

NEONATOLOGY TODAY

News and Information for BC/BE Neonatologists and Perinatologists

Volume 4 / Issue 7
July 2009

IN THIS ISSUE

Inverse Ratio Ventilation in Very Premature Infants

by Dr. med. Hans-Georg Topf;
Dr. med. Raktima Chakrabati;
Prof. Wolfgang Rascher and
PD. Michael Schroth
Page 1

Breakage of a PICC Line

Commentary by Vesselin Dimov,
MD
Page 6

DEPARTMENTS

Medical News, Products and Information

Page 9

NEONATOLOGY TODAY

Editorial and Subscription Offices
16 Cove Rd, Ste. 200
Westerly, RI 02891 USA
www.NeonatologyToday.net

Neonatology Today (NT) is a monthly newsletter for BC/BE neonatologists and perinatologists that provides timely news and information regarding the care of newborns and the diagnosis and treatment of premature and/or sick infants.

© 2009 by Neonatology Today ISSN: 1932-7129 (print); 1932-7137 (online). Published monthly. All rights reserved.

Statements or opinions expressed in Neonatology Today reflect the views of the authors and sponsors, and are not necessarily the views of Neonatology Today.

Recruitment Ads - Pages: 2 and 11

Inverse Ratio Ventilation in Very Premature Infants

By Dr. med. Hans-Georg Topf;
Dr. med. Raktima Chakrabati;
Prof. Wolfgang Rascher and
PD. Michael Schroth

Keywords

- Inverse ratio ventilation
- Very premature infants
- Bronchopulmonary dysplasia
- High frequency oscillation
- High frequency ventilation

We report on two very premature infants who were treated with high frequency inverse ratio ventilation (IRV) as a rescue method for oxygenation. This stems from a concern of possible ventilator-induced lung injury and an impression of improved gas exchange with IRV.¹⁻⁹ Whether IRV improves gas exchange in adult ARDS relative to conventional modes of ventilation has not been shown definitively.^{1-3, 9-12} To our knowledge, to date there is little data about the prolongation of the inspiration time or IRV in children¹³⁻¹⁵ and no data about IRV in premature infants or very premature infants. We want to report our experience with two very premature patients of our neonatal intensive care unit (NICU).

Case 1

Our first patient was a very premature female child with a birth weight of 640 g and a gestational age of 24+1 weeks. The mother has received steroids for lung matu-

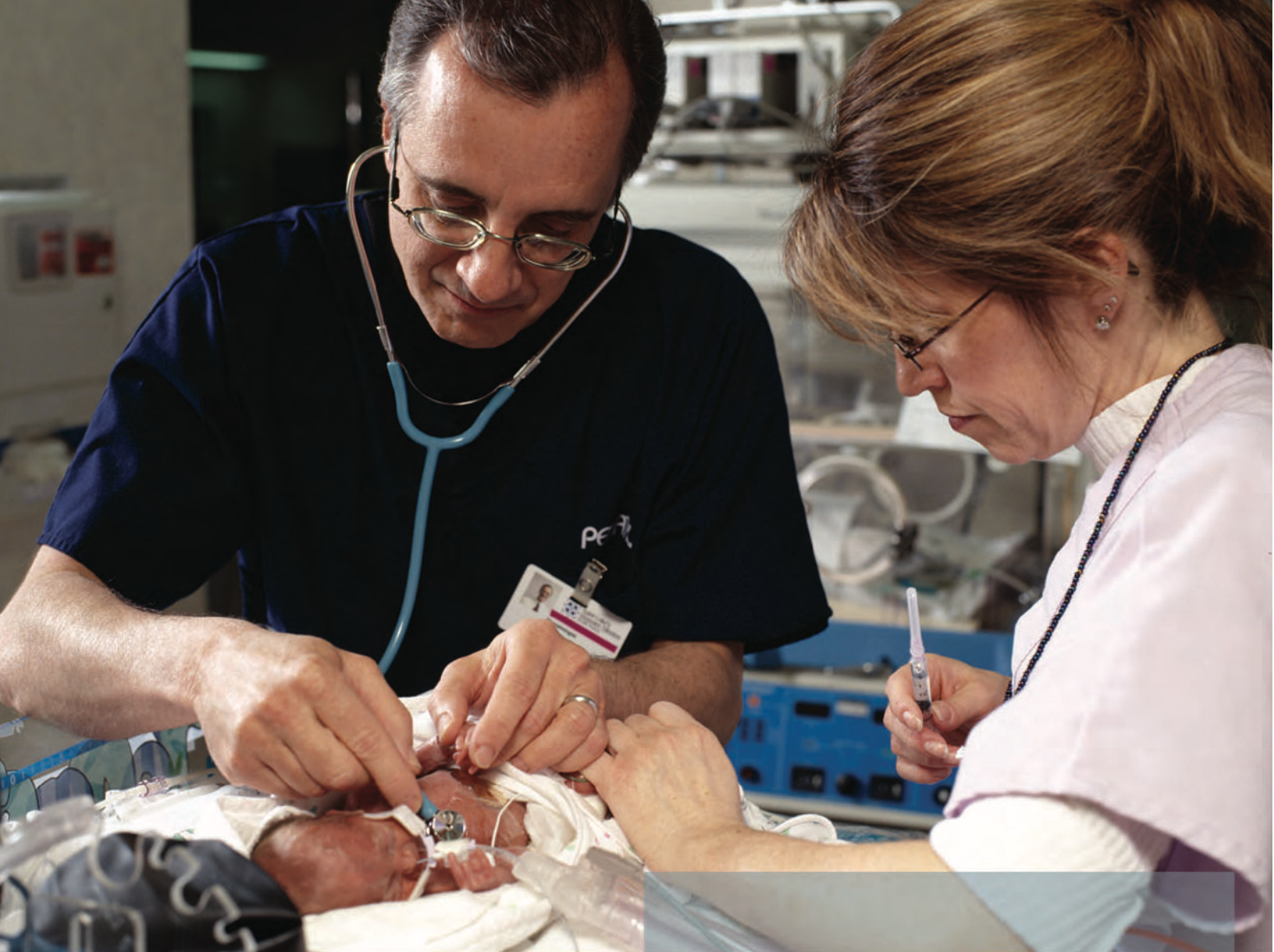ration. Due to insufficient breathing, intubation and surfactant application were performed. At our NICU high frequency oscillation (HFO, sensor medics) was performed with 21% oxygen. Blood gas values were in a good range at all times. Piperacillin and tobramycin were given according to our guidelines. At day 4, a persisting ductus arteriosus (PDA) was observed, which was successfully closed medically with indomethacin. Simultaneously ventilation parameters and oxygen supply needed to be increased. Arterial carbon dioxide was always stable. At day 8 the child became more and more unstable and oxygenation was hardly possible with volume recruitment, changing the ventilation mode to SIMV. Further on CO₂ level was increased, blood pH decreased and inspiration levels of oxygen were up to 70%. Switching back to HFO did not solve the problem. The x-rays of the lung showed diffuse infiltrations and emphysema. At day 12 nitric oxide

“We report on two very premature infants who were treated with high frequency inverse ratio ventilation (IRV) as a rescue method for oxygenation.”

Do you or your colleagues have interesting research results, observations, human interest stories, reports of meetings, etc. that you would like to share with the neonatology community?

Submit a brief summary of your proposed article to:
Article@Neonate.biz

The final manuscript may be between 400-4,000 words, contain pictures, graphs, charts and tables.



Celebrating 30 years of patient care



Pediatrix Medical Group recently reached another milestone in its 30-year history; its clinical data warehouse grew to more than 570,000 total patients and 11 million patient days. Drawing on this extensive data and collective experience, our neonatologists continue to work in a collaborative environment, exchanging ideas, introducing continuous quality improvement initiatives and launching clinical research studies on a national scale.

We thank our physicians for their ongoing dedication and unwavering commitment to improving patient care and advancing evidence-based medicine.

Please contact us to learn about neonatology positions in:

Tampa, Florida	Tulsa, Oklahoma
Albuquerque, New Mexico	Palm Springs, California
Elmira, New York	San Antonio, Texas
	West Texas

800.243.3839, extension 6512
fax 800.765.9859 physician_recruit@pediatrix.com

*To learn more about positions available in other locations,
please visit our Web site at www.pediatrix.com/careers.*

treatment with a maximum of 40ppm was without success. Inspiratory oxygen was 1.0 at this time and arterial saturation around 85%. At day 14 ventilation was now changed from HFO to pressure control (pc) IRV I:E=2:1 as rescue ventilation at a frequency of 60/min. Afterwards, FiO_2 could be reduced to 0.7 the first day and 0.4 after 3 days. Ten days later ventilation could be changed to conventional SIMV ventilation again. Catecholamines were not needed at any time during the ventilation changes.

We could discharge the infant at the age of 3 months in stable condition without BPD.

Case 2

Our second patient was premature male child with a birth weight of 770g and a gestational age of 29 weeks. The boy was transferred to our NICU because of necrotizing enterocolitis (NEC). He was operated at day 3 and parts of the jejunum had to be removed and a stoma was formed. In the following days the patient suffered from an atypical pneumonia, so we added erythromycin to our standard antibiotics piperacillin and tobramycin, and diflucane as antifungal medication. PDA was not detected, blood pressure and diuresis were well. Feeding developed as expected. Catecholamines were not needed after operation. At day 10 the patient developed increasing hypercapnia, so we changed ventilation to HFO. Still, increasing inspiratory O_2 was needed. During the following days inspiratory O_2 had to be increased up to 0.7. By changing ventilation to pClRV at a frequency of 60/min we could reduce FiO_2 to 0,3, without any increase in CO_2 . Several attempts to change ventilation back to normal ratio, SIPPV, or any other method were not sufficient. Steroids, erythromycin or antifungal medication did not help either. So pClRV at a ratio of I:E = 2:1 was performed for 20 days with success. Afterwards ventilation was slowly changed to normal I:E ratio and extubation could be performed at day 42 after short dexa-

mathason treatment. The patient still needed 0.4 FiO_2 , but breathing was sufficient with binasal pronx. After 2 months oxygen still had to be given at a flow of 0.1l/min, and the boy left our clinic at the age of 3 months still in need of oxygen supply at 0,05l/min.

Discussion

The standard method for ventilating the hypoxic premature patient with poor lung compliance and respiratory failure is pressure controlled ventilation using PEEP and moderate to high concentrations of inspired oxygen. The substitution of surfactant after the first days of life is neither beneficial nor conventional. Severely ill patients may not be adequately ventilated with conventional ventilation. Some patients may benefit from HFO if the main problem is hypercapnia. If oxygen supply is the main problem, the same patients frequently suffer from complications of high levels of positive inspiratory pressure (PIP) and positive endexpiratory pressure (PEEP) which include decreased cardiac performance, fluid retention, barotrauma, and pulmonary parenchymal damage.¹⁶

Additionally, oxygen toxicity is a serious problem, especially if high concentrations of inspired oxygen are required for a prolonged period. Retinopathy prematurum and bronchopulmonary dysplasia are common problems in very premature infants, who have to be ventilated with high levels of oxygen. pClRV provides an alternative method of ventilation for these patients. Reynolds described improvement in infants with Hyaline Membrane Disease ventilated with prolonged inspiratory time and pressure-limited ventilation.¹⁷ These findings were confirmed by Reynolds and Taghizadek,¹⁸ and Manginello and coworkers.¹⁹ The characteristics of this form of ventilation are ideally suited for difficult-to-ventilate patients with hypoxia and noncompliant lungs.

Several investigators have demonstrated the usefulness of this approach in the

“In our patients we were able to significantly reduce PIP, provide greater tidal volume and provide adequate ventilation. By using pClRV it is possible to overcome a critical opening pressure during inspiration.”

ventilation of adults with ARDS.² PIP can be reduced and an increase in middle airway pressure observed. The increased middle airway pressure improves oxygenation. The incidence of barotraumas may be reduced by reduced PIP.

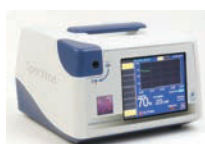Pohlandt and coworkers published an interesting randomised multicentre trial, comparing high versus low rate positive pressure ventilation, concluding that the high rate ventilation regime (60/min, I:E=1:2) changing tidal and minute volumes only via PIP seems beneficial to reduce barotraumas in preterm infants. The benefit was not confirmed in the most immature subgroup (<28 weeks), speculating further reduction of the inspiration time (IT) and increase in rate could be beneficial. The low frequency group allowed an IT of one second at a frequency of 30/min.²⁰

In the OCTAVE study group²¹ high frequency positive pressure ventilation was used with a fixed rate 60/min and I:E ratios from 1:2 to 1:1 were applied. Among all infants this regime reduced the amount of pneumothoraces, but there was no significant reduction in overall mortality or incidence of chronic



T-Stat Tissue Oximeter

**Real-Time
Continuous
Non-Invasive
Ischemia Monitoring**



Spectros

Tisse oxygen management just got easier with the use of VLS, Visible Light Spectroscopy, by SPECTROS

Spectros is the leader in Tissue Oximetry Monitoring using VLS with easy to use and non-invasive probes that are approved for up to 30 days.

When you care about accurate and reproducible results, you can turn to SPECTROS. Make the difference today with early diagnosis and better outcome. Call today.

www.spectros.com

1 877 TSTAT 303

lung disease, or neurodevelopmental outcome.

In our patients we were able to significantly reduce PIP, provide greater tidal volume and provide adequate ventilation. By using pClRV it is possible to overcome a critical opening pressure during inspiration. This pressure is maintained for a sufficiently long period of time to recruit more alveoli despite different retraction forces. In PclRV there is less time for alveolar collapse during expiration due to the shortened expiratory time. With IPPV, middle airway pressure has generally been increased by adding PEEP to prevent alveolar collapse and thus also improves oxygenation. With IPPV in patients with noncompliant lungs the already existing high PIP and the addition of PEEP further increases the PIP. By using PclRV, the middle airway pressure can be increased to improve oxygenation while lowering the PIP. PclRV allows ventilation of additional alveoli and improves functional residual capacity. This method for ventilation provides an initial insufflation time which quickly attains the preset pressure which is then maintained with a decelerating flow pattern throughout the inspiratory phase. The prolonged inspiratory time due to the inverse ratio leads to a more even distribution of gas. The improvement in PaO₂ was documented in blood gas determinations and transcutaneous saturation measurements. Conventional ventilation methods may lead to lung damage including emphysema, interstitial fibrosis, obliterative bronchiolitis and bronchopulmonary dysplasia due to high levels of PIP and PEEP. PclRV may avoid the development of such injuries to the lung by allowing adequate oxygenation and ventilation with a lower PIP and the absence of or utilization of a much reduced level of PEEP.

In addition, the threat of pneumothorax and subcutaneous emphysema is constantly present when utilizing high pressures to ventilate noncompliant lungs. Our patients support the use and further study of PclRV as an alternative approach to ventilatory support in the difficult to oxygenate and ventilate premature

patient. It appears useful in patients who require high levels of inspiratory O₂, PEEP and PIP while on conventional ventilation or high middle pressure on HFO. Although there seem to be many beneficial effects some negative side effects and dangers have to be mentioned. Because of the non-physiological inspiration time there is a higher likelihood of gas trapping, which could lead to significant auto PEEP. This could reduce cardiac output and increase the risk of pneumothorax.¹⁵ In many reports there is a higher need for sedation. In our premature infants neither sedation was needed, nor did we see any significant air trapping or other negative side effects.

It seems that in our setting we were able to combine the benefits of pClRV and of high frequency positive pressure ventilation. Further studies are needed to describe the possible beneficial role of high frequency pClRV in premature infants with respiratory failure.

The institutional review board waived the need for approval.

References

1. Abraham, E. and G. Yoshihara, Cardiorespiratory effects of pressure controlled inverse ratio ventilation in severe respiratory failure. *Chest*, 1989. 96(6): p. 1356-9.
2. Gurevitch, M.J., et al., Improved oxygenation and lower peak airway pressure in severe adult respiratory distress syndrome. Treatment with inverse ratio ventilation. *Chest*, 1986. 89(2): p. 211-3.
3. Lain, D.C., et al., Pressure control inverse ratio ventilation as a method to reduce peak inspiratory pressure and provide adequate ventilation and oxygenation. *Chest*, 1989. 95(5): p. 1081-8.
4. Marini, J.J., Inverse ratio ventilation--simply an alternative, or something more? *Crit Care Med*, 1995. 23(2): p. 224-8.
5. Munoz, J., et al., Pressure-controlled ventilation versus controlled mechanical ventilation with

"It seems that in our setting we were able to combine the benefits of pClRV and of high frequency positive pressure ventilation. Further studies are needed to describe the possible beneficial role of high frequency pClRV in premature infants with respiratory failure."

decelerating inspiratory flow. *Crit Care Med*, 1993. 21(8): p. 1143-8.

6. Poelaert, J.I., et al., Acute hemodynamic changes of pressure-controlled inverse ratio ventilation in the adult respiratory distress syndrome. A transesophageal echocardiographic and Doppler study. *Chest*, 1993. 104(1): p. 214-9.
7. Shanholtz, C. and R. Brower, Should inverse ratio ventilation be used in adult respiratory distress syndrome? *Am J Respir Crit Care Med*, 1994. 149(5): p. 1354-8.
8. Slutsky, A.S., Mechanical ventilation. American College of Chest Physicians' Consensus Conference. *Chest*, 1993. 104(6): p. 1833-59.
9. Tharratt, R.S., R.P. Allen, and T.E. Albertson, Pressure controlled inverse ratio ventilation in severe adult respiratory failure. *Chest*, 1988. 94(4): p. 755-62.
10. Marini, J.J. and B.H. Culver, Systemic gas embolism complicating mechanical ventilation in the adult respiratory distress syndrome. *Ann Intern Med*, 1989. 110(9): p. 699-703.
11. Parker, J.C., et al., Lung edema caused by high peak inspiratory pressures in dogs. Role of increased

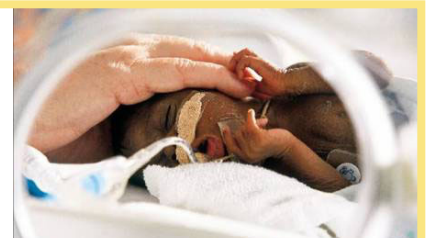

NEO - The Conference for Neonatology
February 11-14, 2010

Hilton - Waldorf Astoria Bonnet Creek, Orlando, FL

www.neoconference.com

One of the Premier Meetings in Neonatal Medicine!



“In our patients we were able to significantly reduce PIP, provide greater tidal volume and provide adequate ventilation.”

microvascular filtration pressure and permeability. *Am Rev Respir Dis*, 1990. 142(2): p. 321-8.

12. Webb, H.H. and D.F. Tierney, Experimental pulmonary edema due to intermittent positive pressure ventilation with high inflation pressures. Protection by positive end-expiratory pressure. *Am Rev Respir Dis*, 1974. 110(5): p. 556-65.
13. Carpenter, T., Novel approaches in conventional mechanical ventilation for paediatric acute lung injury. *Paediatr Respir Rev*, 2004. 5(3): p. 231-7.
14. Goldstein, B. and P.J. Papadakos, Pressure-controlled inverse-ratio ventilation in children with acute respiratory failure. *Am J Crit Care*, 1994. 3(1): p. 11-5.
15. Prodhon, P. and N. Noviski, Pediatric acute hypoxemic respiratory failure: management of oxygenation. *J Intensive Care Med*, 2004. 19(3): p. 140-53.
16. Lachmann, B., et al., Modes of artificial ventilation in severe respiratory distress syndrome. Lung function and morphology in rabbits after wash-out of alveolar surfactant. *Crit Care Med*, 1982. 10(11): p. 724-32.
17. Reynolds, E.O., Effect of alterations in mechanical ventilator settings on pulmonary gas exchange in hyaline membrane disease. *Arch Dis Child*, 1971. 46(246): p. 152-9.
18. Reynolds, E.O. and A. Taghizadeh, Improved prognosis of infants mechanically ventilated for hyaline membrane disease. *Arch Dis Child*, 1974. 49(7): p. 505-15.

19. Manginello, F.P., et al., Evaluation of methods of assisted ventilation in hyaline membrane disease. *Arch Dis Child*, 1978. 53(11): p. 878-81.
20. Pohlandt, F., et al., Decreased incidence of extra-alveolar air leakage or death prior to air leakage in high versus low rate positive pressure ventilation: results of a randomised seven-centre trial in preterm infants. *Eur J Pediatr*, 1992. 151(12): p. 904-9.
21. Multicentre randomised controlled trial of high against low frequency positive pressure ventilation. Oxford Region Controlled Trial of Artificial Ventilation OCTAVE Study Group. *Arch Dis Child*, 1991. 66(7 Spec No): p. 770-5.

NT

Corresponding Author

*Dr. med. Hans-Georg Topf
Kinderklinik Erlangen
Germany*

*Tel: +49/9131/8533118
Fax: +49/9131/8533113*

hgtopf@email.de

*Dr. med. Raktima Chakrabati
Kinderklinik Erlangen
Germany*

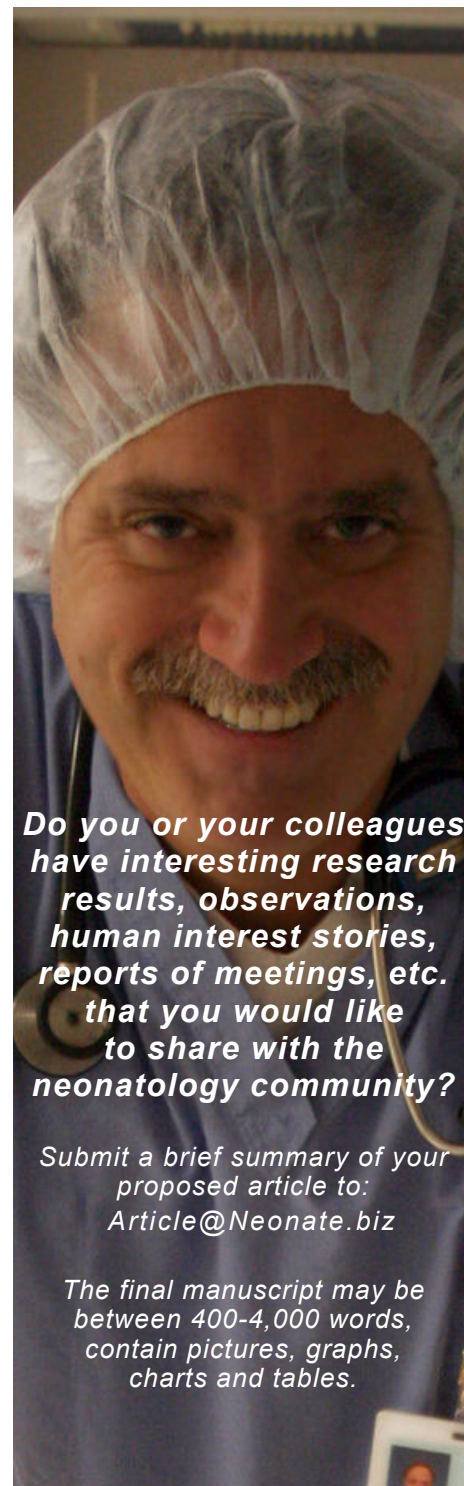michael.schroth@uk-erlangen.de

*Prof. Wolfgang Rascher
Kinderklinik Erlangen
Germany*

wolfgang.rascher@uk-erlangen.de

*PD. Michael Schroth
Kinderklinik Erlangen
Germany*

michael.schroth@uk-erlangen.de

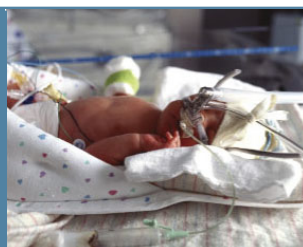

Do you or your colleagues have interesting research results, observations, human interest stories, reports of meetings, etc. that you would like to share with the neonatology community?

*Submit a brief summary of your proposed article to:
Article@Neonate.biz*

The final manuscript may be between 400-4,000 words, contain pictures, graphs, charts and tables.

SPECIALTY
REVIEW IN
**Neonatology/
Perinatology
2.0**



Dr. Dharmapuri Vidyasagar
in collaboration with
Pediatrix Medical Group

February 12-16, 2010
Orlando, FL
www.pediatrix.com/specialtyreview

Save the Date



Breakage of a PICC Line

Commentary by Vesselin Dimov, MD

Dimov V. Breakage of a PICC Line [Spotlight]. AHRQ WebM&M [serial online]. April 2009. Available at: <http://www.webmm.ahrq.gov/case.aspx?caseID=197>

Republished here with permission. All rights reserved, AHRQ WebM&M

Case Objectives

- Appreciate the incidence and consequences of PICC line breakage.
- Understand the risk factors for PICC line breakage.
- Understand the treatment options in case of PICC line breakage.
- Understand the measures to safely place a PICC line and prevent PICC line breakage.
- Appreciate the guidelines to reduce risk of complications from central venous catheters.

The Case

Born at 27 weeks' gestation, a premature infant had a standard, silastic, 1.9 F percutaneously inserted central venous catheter (PICC) placed on day two of life for parenteral nutrition. The PICC was inserted under sterile conditions with placement verified by X-ray. Initially, the infant was on ventilator support and NPO due to feeding intolerance and necrotizing enterocolitis surveillance. Several attempts were made to introduce feeds; however, the infant continued to have large residuals and increased abdominal girth.

After 40 days of parenteral therapy, the antecubital site and the upper arm became red, swollen, and tender to the touch. The neonatologist opted to remove the catheter. When the RN started to remove the PICC, it broke, leaving approximately 7 cm in the patient.

After several attempts to retrieve the remainder of the line, with X-rays to check placement, the infant was sent for surgical removal of the catheter. Cultures taken via blood and PICC reported moderate growth of *Staphylococcus*. The infant required an increased level of care that included ventilator support, infusion of blood products, and antibiotic treatment.

The Commentary

Venous access is of critical importance in sick neonates. Patients in neonatal intensive care units (NICUs) often require parenteral antibiotics for treatment of sepsis or other infections, total parenteral nutrition (TPN), and life support medications. In addition, neonates have large fluid losses because of their relatively large body surface area, which increases their need for reliable access to deliver hydration.¹

Peripherally inserted central catheters (PICCs) were introduced in 1975 as an alternative to tunneled central catheters (Hickman lines) and ports (e.g., Portacaths).² These catheters, which are made of silicone, polyurethane, or polyethylene, are generally inserted in the antecubital fossa by interventional radiologists or members of a PICC team, often using ultrasonic or fluoroscopic guidance.

PICCs are being used with increasing frequency for several reasons, not only in the NICU setting but also in the general inpatient and outpatient pediatric population. First, the increasing use is related to the availability of these devices, and the increasing availability of specialized PICC teams to insert them. Second, PICCs have a lower risk of complications than tunneled central venous lines.^{3,4} Third, the procedure is simpler to perform than insertion of tunneled catheters and can be done rapidly, relatively inexpensively, and with only mild sedation or pain relief.

Turning specifically to neonates, there are other reasons that PICCs have become increasingly attractive. The catheters are widely available in sizes as small as 1.2 F, facilitating insertion in micropremies weighing less than 500 g to 700 g.⁵ Moreover, they have been shown to reduce the length of hospital stay and can reduce the stress and suffering associated with frequent venipuncture in pediatric inpatients during a prolonged hospital stay.⁶

Notwithstanding all these attractive features, PICCs can cause complications. These include injury to vessels or organs during insertion, catheter migration or malposition with extravasation, infection, thromboembolism, catheter breakage (fracture), and dysfunction.⁵ Several retrospective studies have tracked these complications in pediatric populations. One study of 120 inpatients' records found that PICCs were generally placed to administer che-

motherapy, blood transfusions, antibiotics, or parenteral nutrition. All inpatients received fluoroscopic guided PICC (4 F single-lumen silicone rubber catheter) insertions into distal superior vena cava via the antecubital region of the forearm. The study found that the most common complications were wound oozing, phlebitis, occlusion, infection, and leaking.⁷

A second study was a retrospective review of PICC-related complications in 53 pediatric patients with various types of malignancies.⁸ In this population, PICCs were used to administer fluid, parenteral nutrition, anticancer agents, antibiotics, and blood products and also for the through-line blood sampling. PICCs were successfully placed in 109 of 112 attempts (97.3%) in 53 patients, and they were followed for a total of 11,797 catheter days. Fifty-five PICCs (50.5%) were removed as a result of PICC-related complications, yielding a complication rate of 4.66 per 1000 catheter days. The most common reasons for catheter removal were occlusion (n=18), breakage/leakage (n=15), and infection (n=10). Because more than 70% of such complications occurred more than 30 days after placement, the authors concluded that longer-term placement of PICCs may be related to an increased risk of complications.⁸

The case presented here describes a relatively rare PICC complication: breakage that occurs while the PICC is in the intravascular space.

Only one study in the literature examines the complication of PICC breakage in sufficient detail to analyze possible risk factors and review outcomes. A retrospective study examined the records of PICC insertions in a single tertiary care pediatric hospital over a 6-year period.⁹ Among approximately 1650 PICCs, the most common complications were mechanical and accidental failures of the catheter (leaks, accidental removal, migration of the tip, fracture, and embolization), PICC-related infections, occlusion of the PICC (chemical, mechanical, or thrombotic), venous or right atrial perforation, arrhythmias, and venous stasis causing phlebitis. In this study, 11 children were identified with a fractured PICC line, an incidence of 6.7 per 1000 PICCs. All fractured lines were 3 F or 4 F in size and were inserted in the upper extremities; 75% of control patients had the same type of PICCs placed. Patient characteristics did not reveal any specific risk factors for intra-

vascular PICC fracture, nor were catheter size, insertion site, and specific medications infused through the line significant predictors of fracture.⁹

On the other hand, catheter fractures were more common in older lines and when there was evidence of another complication with the line (blockage of the line, leaking at the insertion site, or history of difficulty flushing the line with heparin). The median time from insertion to discovery of the PICC fracture was 93 days, consistent with the hypothesis that catheter fatigue plays a role in breakage. Only two catheters fractured less than 2 months after insertion. All catheters were fractured at or near the entrance site. Together, these data support the hypothesis that catheter fatigue and stress play a role in breakage. The investigators speculate that mechanical manipulation (particularly rotational torque or twisting of the catheter) may be more likely to promote fatigue and breakage than linear bending, and that flushing blocked lines under high pressure (using too much manual force or using small syringes) may also contribute to breakage.

The complication of PICC breakage may be discovered in a variety of ways. In four cases each, the fracture was identified by chest roentgenography or on fluoroscopy before contrast injection. Two fractured lines were discovered at the time of line removal; the remaining case was identified during cardiac catheterization for myocardial biopsy.

In all cases, the embolized line fragment was successfully retrieved by percutaneously inserted catheters and snares. Although no major complications arose from the fractured catheters in the case series,⁹ the transvenous removal of a PICC fragment from the circulation may be challenging, especially in neonates born prematurely or with very low birth weight. The child described in the present case required surgery for removal of the PICC fragment.

The most commonly used nonsurgical method of PICC fragment removal is snaring the line and pulling it into a sheath that is then pulled out of the body. This is most often accomplished under direct visualization by an interventional radiologist. The migration of the embolized fragment usually does not lead to hemodynamic instability, even when it enters the heart or lungs. The size and weight of the child present several challenges to successful PICC fragment removal. The challenges with preterm interventions include those related to access, maintenance of homeostasis (hypothermia, hypoglycemia) during the procedure, and negotiating the curves within the vascular structures.^{10,11}

What can we learn about this unusual complication from this case? When using PICCs in neonates, the small size of the line (1.9 F [0.64 mm] in this case) can make it difficult to prevent kinks and other damage. The fact that the site underwent repeated sterile dressings and had been in place for more than a month might have led to its fragility. The catheter's small size and intravascular location would also facilitate fibrin binding, keeping it secure in the vessel and making it more likely to break on removal. Another factor

was the use of a small syringe for flushing. According to the case reporter, after this case was reviewed, the hospital mandated that a syringe with a volume greater than 5 mL be used when flushing the line. Chow and colleagues have hypothesized that the use of small syringes (5 mL or less) could lead to increased force on catheter walls and higher risk of fractures.⁹

Table. Guidelines to reduce risk of complications from central venous catheters.

- Use strict aseptic precautions for insertion and maintenance of the catheter, including dressing changes, tubing connections, and medication administration.
- Ensure that blood can be aspirated freely into the catheter when it is inserted before it is taped into position. Confirm the location of the catheter tip radiographically (using radio-opaque contrast if necessary) on initial insertion. Repeat radiographs if there is any question of catheter movement or malfunction. Scrutinize radiographs obtained for any reason for appropriate catheter position.
- The tip of the central venous catheter (CVC) should be just above the superior vena cava/right atrium junction for insertions from the upper extremity and at the IVC/right atrium junction for insertions from the lower extremity or the umbilical venous catheter.
- Inspect the insertion site daily. Transparent dressings should be changed every 7 days except when the risk of dislodging the catheter outweighs the benefit of changing the dressing. Replace all damp, loose, or soiled dressings.
- Add 0.5 to 1.0 mL of heparin per mL of intravenous fluids being infused.
- Remove catheter as soon as medically feasible if it is obstructed or if there is evidence of thrombosis or infection.

Because PICC breakage is so unusual, it is difficult to formulate a set of evidence-based recommendations to prevent the complication. Nevertheless, based on the experience in the literature, some recommendations can be made (Table). It seems prudent to avoid flushing catheters under high pressure or using small syringes. Although PICC line duration is clearly a risk factor for breakage, routine removal and reinsertion also carry risks and costs and cannot be recommended at this time. Catheter tips should be in the superior vena cava (having the tip in a large-lumen vessel may decrease the risk of local complications); this position should be monitored frequently by radiographs or ultrasound.^{12,13} PICCs should be removed as soon as the indication for them is no longer present. Some investigators have called for the development of a new material or surface coating on the PICC line to prevent fibrin adherence.⁷

Health care professionals and parents responsible for maintaining PICCs (since many patients go home with these lines, where they are cared for by patients and families) should be informed about



**Contemporary Management of Neonatal
Pulmonary Disorders Conference**

October 29 - 30, 2009; Tempe Mission Palms, Tempe, Arizona
Contact: Cathy Martinez (602) 277-4161 x 11 Fax: (602) 265-2011
E-mail: cathy@nalweb.com

www.nalweb.com/cmnpdconference

PowerPoint® Slideshow on this Article Available Online

<http://www.webmm.ahrq.gov/slideshows/webmm.ahrq.gov.197.slideshow.ppt>

the possibility of PICC breakage during the informed consent process, and should be educated about the phenomenon of PICC fracture and the signs to watch for: difficulty flushing or withdrawing from the line and leaking at the site of insertion. Such problems should be promptly investigated, because PICC complications are potentially life-threatening. A chest roentgenogram, including a view of the arm with the insertion site, should be performed initially, followed by fluoroscopy if the catheter appears intact. In addition, caregivers should be warned against flushing with small-volume syringes.⁹

“Take-Home” Points

For a variety of reasons, use of PICCs has become increasingly prevalent, including in pediatric inpatients.

PICC complications include: injury to other vessels or organs during insertion, catheter migration or malposition with extravasation from the malpositioned catheter, infection, thromboembolism, catheter breakage, and dysfunction.

Over the course of a case series of 1650 PICCs, fracture and embolization occurred at an incidence of 6.7 in 1000 PICCs.⁹ Duration of placement and a line complication (blockage of the line or leaking at the insertion site) are associated with PICC fractures.

Caregivers should be warned against flushing PICCs with small-volume syringes or with too much pressure.

Faculty Disclosure: *Dr. Dimov has declared that neither he, nor any immediate member of his family, has a financial arrangement or other relationship with the manufacturers of any commercial products discussed in this continuing medical education activity. In addition, the com-*

mentary does not include information regarding investigational or off-label use of pharmaceutical products or medical devices.

CME Credit

AHRQ WebM&M offers continuing medical education (CME) credit for physicians and continuing education units (CEU) for nurses for completion of Spotlight modules. Credit is available only for physicians and nurses, although physicians assistants may be eligible (see below; please contact the American Academy of Physician Assistants for more information).

To obtain CME, CEU, or trainee certification, you must be registered for CME/CEU and logged in to the CME/CEU portion of site.

For more information about CME/CEU: <http://www.webmm.ahrq.gov/cmeAbout.aspx>

References

- Hogan MJ. Neonatal vascular catheters and their complications. *Radiol Clin North Am.* 1999;37:1109-1125.
- Goodwin ML, Carlson I. The peripherally inserted central catheter. *J Intraven Nurs.* 1993;16:92-103.
- Rountree D. The PIC catheter: a different approach. *Am J Nurs.* 1991;91:22-62.
- Denny DF Jr. Placement and management of long-term venous access catheters and ports. *Am J Roentgenol.* 1993;161:385-393.
- Ramasetu J. Complications of vascular catheters in the neonatal intensive care unit. *Clin Perinatol.* 2008;35:199-222.
- Stovroff MC, Totten M, Glick PL. PIC lines save money and hasten discharge in the care of children with ruptured appendicitis. *J Pediatr Surg.* 1994;29:245-247.
- Leung TK, Chang CP, Lee CM, Shen LK. Retrospective study of the total insertion period of peripherally inserted central catheter: discussion of anti-thrombogenic surface and other biomaterial requirements. *Biomed Mater Eng.* 2006;16:183-188.
- Matsuzaki A, Suminoe A, Koga Y, Hatano M, Hattori S, Hara T. Long-term use of peripherally inserted central venous catheters for cancer chemotherapy in children. *Support Care Cancer.* 2006;14:153-160.
- Chow LM, Friedman JN, Macarthur C, Restrepo R, Temple M, Chait PG, et al. Peripherally inserted central catheter (PICC) fracture and embolization in the pediatric population. *J Pediatr.* 2003;142:141-144.
- Kohli V, Joshi R. Central line retrieval in a neonate. *Indian J Pediatr.* 2007;74:692-693.
- Robbins AB, Patel H. Transvascular retrieval of a catheter remnant from the peripheral vein of a preterm neonate. *J Vasc Access.* 2008;9:299-300.
- Coit AK, Kamitsuka MD; Pediatric Medical Group. Peripherally inserted central catheter using the saphenous vein: importance of two-view radiographs to determine the tip location. *J Perinatol.* 2005;25:674-676.
- Schwengel DA, McGready J, Berenholtz SM, Kozlowski LJ, Nichols DG, Yaster M. Peripherally inserted central catheters: a randomized, controlled, prospective trial in pediatric surgical patients. *Anesth Analg.* 2004;99:1038-1043.

NT

*Vesselin Dimov, MD
Allergy and Immunology Fellow
Division of Allergy and Immunology
Creighton University
Omaha, Nebraska
Former Clinical Assistant Professor
of Medicine
Cleveland Clinic Lerner College of
Medicine of Case Western Reserve
University
Cleveland, OH USA*

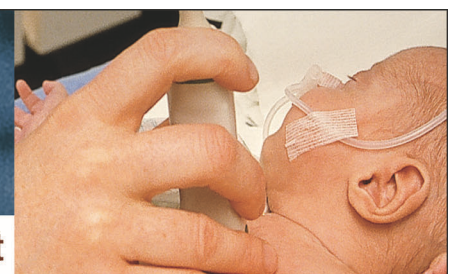
**OPTIMIZING THE
MANAGEMENT OF**

pda

*Join us for a free
on-demand webcast*

DEC 2008 — NOV 2009

www.5StarMedEd.org/pda-management



Medical News, Products and Information

Researchers Identify the Gene Responsible for a Rare Form of Congenital Anemia

A May electronic edition of the journal *Nature Genetics* reports the discovery of a new gene responsible for congenital sideroblastic anemia, a rare disease, mainly characterized by the presence of ringed sideroblasts in the patients' bone marrow. This Genome Canada project, co-directed by Dr. Mark Samuels, an investigator with the Sainte-Justine University Hospital Research Center and a professor at the Université de Montréal Department of Medicine, is being conducted under the Atlantic Medical Genetics and Genomics Initiative (AMGGI).

The clinical research team identified three families from Canada's Maritime provinces, each with a child suffering from this disease. Even though these families were not related officially, it seemed very likely that it was possible to establish a genealogical link uniting them generations ago and that they exhibited what is called a founder effect.

Thanks to the new technologies developed by the Human Genome Project, the AMGGI's molecular analysis team succeeded in delimiting a genomic region likely to contain the gene responsible for congenital sideroblastic anemia in these families.

The direct resequencing of this gene made it possible to identify a causal mutation in a gene to which no physiological role could have been attributed. Subsequently, in collaboration with researchers in the United States, the team identified 10 additional causal mutations of this gene in other unexplained cases of congenital sideroblastic anemia. In collaboration with the laboratory of Dr. Louis Saint-Amant of the Université de Montréal's Department of Pathology, the research team showed a direct role of the gene in hemoglobin synthesis in zebra fish.

The gene identified is part of a gene family involved in the transport of nutrients to and from the mitochondria, the power plant of

the cells. Some mutations of other members of this gene family cause distinct genetic diseases in humans, but this is the first disease of this type associated with the SLC25A38 gene.

The identification of the causal gene can now offer patients and their family members direct molecular confirmation of their condition, allowing them to know whether they are sufferers or asymptomatic carriers of the disease. More generally, this discovery shows that even well-known scientific processes, such as hemoglobin biosynthesis, still have surprises in store.

About the Sainte-Justine University Hospital Research Center: www.recherche-sainte-justine.qc.ca/en/
About the Université de Montréal: www.umontreal.ca/english/index.htm

MedImmune Presents New Data Demonstrating Increased Risk for Medically Attended RSV in Late-Preterm Infants

MedImmune has announced results from a recent study it sponsored, performed by the Kaiser Permanente Division of Research in Oakland, CA, assessing risk factors for respiratory syncytial virus (RSV) infection requiring medical treatment in infants born at 33 weeks gestational age [GA] or later. The analysis suggested that even mild prematurity (e.g., babies born 33-36 weeks GA) is associated with increased risk of medically attended RSV infection, and that this risk is higher among infants exposed to supplemental oxygen or assisted ventilation during the neonatal period. These findings were presented at the *2009 Pediatric Academic Societies (PAS) Annual Meeting* in Baltimore, Maryland by Dr. Gabriel J. Escobar.

RSV is a leading cause of viral respiratory infection among preterm infants. Although prematurity is a known risk factor for severe RSV infection, there is little information

available on risk factors among moderately (rather than extremely) premature babies.

"The health risks associated with late-preterm birth may be overlooked or misunderstood because these babies often appear as healthy as full-term infants. This study contributes to the growing evidence that, late-preterm infants face greater morbidity and healthcare costs up to at least one year after birth," noted Parthiv Mahadevia, MD, Senior Director, Health Outcomes and Pharmacoeconomics, MedImmune. "In particular, babies born between 33 and 36 weeks GA have underdeveloped respiratory and immune systems, putting them at heightened risk for severe RSV disease." Doctors, parents, and the health care system should be aware of these babies' specialized health needs

This study sought to quantify the relationships between neonatal characteristics and the occurrence of RSV infection requiring medical attention in the first year of life.

The study consisted of 117,060 babies born at 33 weeks gestation or later, who were discharged from six hospitals between January 1, 1996, and December 31, 2002. The neonatal characteristics evaluated included GA, infant sex, "small for GA" status, oxygen exposure variables, and hospital discharge during the RSV season.

The authors noted that further research is needed to determine whether strategies to prevent or mitigate RSV infection are needed in late-preterm infants.

For more information, visit MedImmune at www.medimmune.com.

Preclinical Work Shows How One Gene Causes Severe Mental Retardation

Researchers at Duke University Medical Center and the University of North Carolina have discovered in mice how a single disrupted gene can cause a form of severe

case reviews in

pda



free on-demand webcast
specifically designed for clinicians treating
patients with patent ductus arteriosus

www.5StarMedEd.org/pda-cases

mental retardation known as Angelman Syndrome.

In a study published in the journal *Nature Neuroscience*, they found that the gene, UBE3A, is needed so that neurons in the brain can form and adjust their connections to other neurons for storing sensory information. They also made a promising discovery: When the mice were deprived of sensory stimulation, the brain connections could be recovered, a finding that indicated a pharmaceutical or behavioral treatment might be possible in the future.

The scientists undertook this project because of the developmental-onset period seen in Angelman Syndrome, typically when children are between one and two years old. It is during this time in humans that the cortex, the sheet of convoluted folds at the surface of the brain, undergoes profound rearrangements driven by sensory experiences – the experience of seeing reorganizes the visual cortex, for example, during the same time period when the deficits are becoming obvious in Angelman Syndrome, part of the autism spectrum of disorders.

"We wanted to look at an animal model to learn if this experience-dependent reorganization of the cortex was abnormal in animals that were missing the gene," said Michael Ehlers, MD, PhD, a Duke Professor of Neurobiology and co-senior author of the study. "We looked at the visual cortex, because in this well-studied model, we could precisely control the sensory stimulus and study the mice in the light or the dark. We speculated that similar deficits may be happening in areas of the cortex that are important for language, cognition and emotion, all of which are quite abnormal in Angelman Syndrome patients."

The authors found that brains cells in Angelman Syndrome mice lacked the ability to appropriately strengthen or weaken in the cortex, an area of the brain important for cognitive abilities. Angelman Syndrome is one among a small family of single gene, autism-related, neurodevelopmental disorders. Children with the condition appear to respond normally to stimuli during their first year, but around 12-18 months, they start missing milestones of cognitive development and language, typically learning only 2-3 words over their lifetime.

"When we have experiences, connections between brain cells are modified so that we can learn," said Ben Philpot, PhD, a University of North Carolina Professor in Cell and Molecular Physiology and co-senior author of the study. "By strengthening and weakening appropriate connec-

tions between brain cells, a process termed synaptic plasticity, we are able to constantly learn and adapt to an ever-changing environment."

"It is difficult to study how experiences lead to changes in the brain in models of mental retardation," said Koji Yashiro, PhD, a former University of North Carolina graduate student and lead author of the study. "Instead of studying a complex learning model, we studied how connections between brain cells change in visual areas of mice exposed to light or kept in darkness. This approach revealed that brain cells in normal mice can modify their connections in response to changes in visual experiences, while the brain cells in Angelman Syndrome mice could not."

The inability of brain cells to encode information from experiences in the Angelman Syndrome model suggested that this is the basis for the profound learning difficulties in these patients.

The scientists didn't expect to find that the plasticity of the cellular connections could be restored in visual areas of the brain after brief periods of visual deprivation.

"By showing that brain plasticity can be restored in Angelman Syndrome model mice, our findings suggest that brain cells in Angelman Syndrome patients maintain a latent ability to express plasticity. We are now collaborating to find a way to tap into this latent plasticity, as this could offer a treatment, or even a cure, for Angelman Syndrome," Philpot said.

Ehlers, who is also a Howard Hughes Medical Investigator, said that perhaps some of these developmental brain disorders are a form of social and cognitive blindness. In a condition known as amblyopia, or cortical blindness, the eye can function normally, but past a critical period, the brain cannot process the sensory input correctly.

"We think that children with Angelman Syndrome may have a condition in which sensory experience dampens down plasticity and affects learning," Ehlers said. "One important aspect of our findings is that sensory manipulations recovered plasticity, suggesting that the underlying substrates for plasticity are intact in mice. If the same thing holds true for the human disease, there may be a chance to improve brain function."

This work was supported by grants from the National Institutes of Health, the Howard Hughes Medical Institute, the Angelman Syndrome Foundation, and the Simons Foundation.

© 2009 by Neonatology Today
ISSN: 1932-7129 (print); 1932-7137 (online).
Published monthly. All rights reserved.

Publishing Management

Tony Carlson, Founder & Senior Editor
TCarlsonmd@gmail.com
Richard Koulbanis, Publisher & Editor-in-Chief
RichardK@Neonate.biz
John W. Moore, MD, MPH, Medical Editor/
Editorial Board
JMoore@RCHSD.org

Editorial Board

Dilip R. Bhatt, MD
Barry D. Chandler, MD
Anthony C. Chang, MD
K. K. Diwakar, MD
Philippe S. Friedlich, MD
Lucky Jain, MD
Patrick McNamara, MD
David A. Munson, MD
Michael A. Posencheg, MD
DeWayne Pursley, MD, MPH
Joseph Schulman, MD, MS
Alan R. Spitzer, MD
Gautham Suresh, MD
Dharmapuri Vidysagar, MD
Leonard E. Weisman, MD
Stephen Welty, MD

FREE Subscription - Qualified Professionals

Neonatology Today is available free to qualified medical professionals worldwide in neonatology and perinatology. International editions available in electronic PDF file only; North American edition available in print. Send an email to: SUBS@Neonate.biz. Include your name, title(s), organization, address, phone, fax and email.

Contacts and Other Information

For detailed information on author submission, sponsorships, editorial, production and sales contact, send an email to INFO@Neonate.biz.

To contact an Editorial Board member, send an email to: BOARD@Neonate.biz putting the Board member's name on the subject line and the message in the body of the email. We will forward your email to the appropriate person.

Sponsorships and Recruitment Advertising

For information on sponsorships or recruitment advertising call Tony Carlson at 301.279.2005 or send an email to RECRUIT@Neonate.biz.

Meetings, Conferences and Symposiums

If you have a symposium, meeting or conference, and would like to have it listed in Neonatology Today, send an email to: MEETING@Neonate.biz. Include the meeting name, dates, location, URL and contact name.

Corporate Offices

9008 Copenhaver Drive, Ste. M
Potomac, MD 20854 USA
Tel:+1.301.279.2005; Fax: +1.240.465.0692

Editorial and Subscription Offices

16 Cove Road, Ste. 200
Westerly, RI 02891 USA
www.NeonatologyToday.net



LOCUM TENENS AND FULL-TIME PLACEMENT

STAND OUT

All the best positions go fast.

Neonatology
Pediatric Critical Care
Pediatric Emergency Medicine
Pediatric Surgery

Let **TIVA** help **YOU**
GET NOTICED!



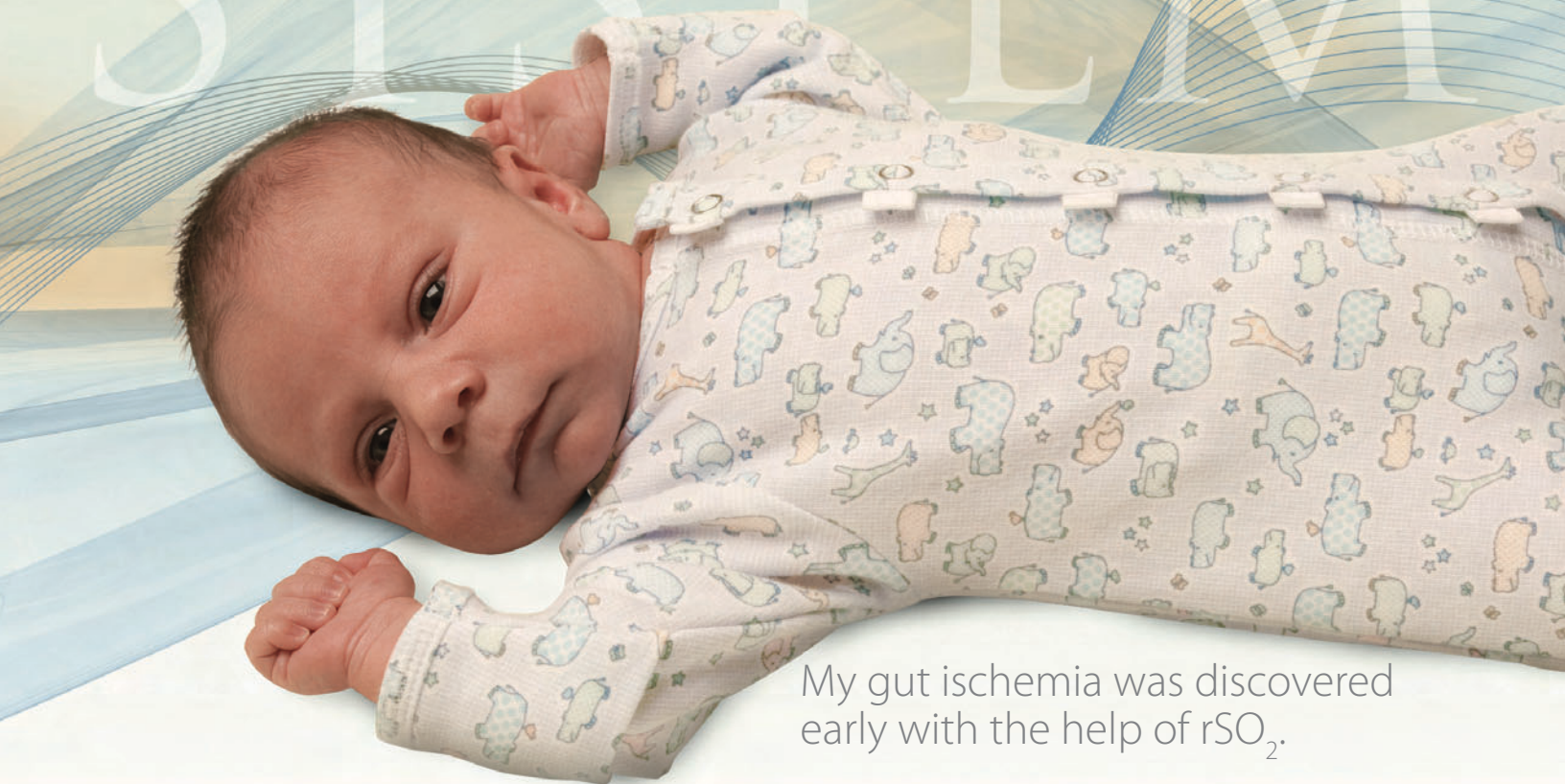Physician Trained Placement Specialists

Neonatology • Anesthesiology • Radiology • Emergency Medicine

800.506.TIVA (8482)
www.tivahealthcare.com
standout@tivahealthcare.com

INVOS

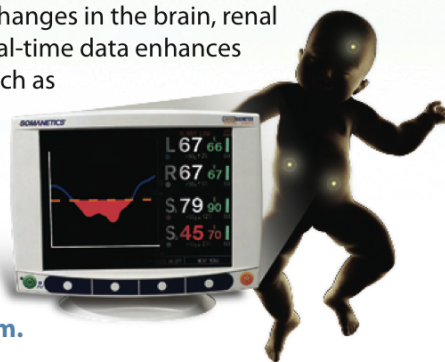
REVEALING PERFUSION IMBALANCE



My gut ischemia was discovered early with the help of rSO_2 .

Enhanced Detection for Rapid Response.

Every patient has unknown clinical variables. Let the INVOS® System help you reveal them. This gentle cerebral/somatic oximeter noninvasively monitors regional oxygen saturation (rSO_2) changes in the brain, renal area, abdomen and other specific sites. Its real-time data enhances detection and response to oxygen threats such as those related to low cardiac output¹, renal dysfunction², neurologic damage³, shock⁴, gut ischemia⁴ and seizures⁵. It also reflects the impact of interventions, so you can assess efficacy and next steps before problems escalate.



INVOS CEREBRAL/SOMATIC
OXIMETER
REFLECTING THE COLOR OF LIFE®

Reveal new insights with the INVOS System.

1. Hoffman GM, et al. Semin Thorac Cardiovasc Surg Pediatr Card Surg Annu. 2005; pp 12-21. 2. Hoffman GM, et al. Anesthesiology 2005; 103:A1327 3. Dent CL, et al. J Thorac Cardiovasc Surg 2005; 130: 1523-30. 4. Kaufman et al. J Ped Crit Care Med 2008; 9:62-8. 5. Diaz GA, et al. Eur J Paediatr Neurol 2006; 10:19-21 © Somanetics Corporation. Somanetics, INVOS and "Reflecting the color of life" are registered trademarks of Somanetics Corporation. US federal regulations restrict the sale of this device to, or on the order of, licensed medical practitioners.

SOMANETICS®

800-359-7662

Come visit our new expanded website at www.somanetics.com