

# NEONATOLOGY TODAY

News and Information for BC/BE Neonatologists and Perinatologists

Volume 5 / Issue 10

October 2010

## IN THIS ISSUE

### Individualized Environments in the NICU

by Robert White, MD  
Page 1

### Subgaleal Hemorrhage Following Vacuum Extraction Vaginal Delivery: A Frequently Undiagnosed Problem

by Houchang D. Modanlou, MD  
Page 6

## DEPARTMENT

### Global Neonatology Today: A Monthly Column

by Dharmapuri Vidyasagar, MD, FAAP, FCCM  
Page 5

### Medical News, Products & Information

Page 9

## NEONATOLOGY TODAY

Editorial and Subscription Offices  
16 Cove Rd, Ste. 200

Westerly, RI 02891 USA

[www.NeonatologyToday.net](http://www.NeonatologyToday.net)

Neonatology Today (NT) is a monthly newsletter for BC/BE neonatologists and perinatologists that provides timely news and information regarding the care of newborns and the diagnosis and treatment of premature and/or sick infants.

© 2010 by Neonatology Today ISSN: 1932-7129 (print); 1932-7137 (online). Published monthly. All rights reserved.

Statements or opinions expressed in Neonatology Today reflect the views of the authors and sponsors, and are not necessarily the views of Neonatology Today.

## Upcoming Meetings

Contemporary Management of Neonatal Pulmonary Disorders Conference  
Nov. 4-5, 2010; Tempe, AZ USA  
[www.nalweb.com/cmnpdconference](http://www.nalweb.com/cmnpdconference)

Hot Topics in Neonatology  
Dec. 5-7, 2010; Washington, DC USA  
[www.hottopics.org](http://www.hottopics.org)

The 24th Annual Gravens Conference on the Physical and Developmental Environments of the High Risk Infant  
Jan. 26-27, 2011; Clearwater Beach, FL USA  
[www.cme.hsc.usf.edu/events.html](http://www.cme.hsc.usf.edu/events.html)

NEO: The Conference for Neonatology  
Feb. 24-27, 2011; Orlando, FL USA  
[www.neoconference.com](http://www.neoconference.com)

Recruitment Ads  
Pages 2 and 11

## Individualized Environments in the NICU

By Robert White, MD

In earlier days, hospital care was provided in large wards. The images are familiar – long rows of children with polio, soldiers with wounds, mothers in one ward, babies in another. Today, these images are replaced with private rooms, often rivaling the finest hotels in amenities. Both business and patient-related outcome measures have led to this change which was resisted at first by both administrators and caregivers, but is now embraced by nearly all as the optimal form of care. In particular, the separation of mothers and babies, previously the norm after a healthy birth, is now seen as unnatural and unnecessary.

The NICU stands in distinct contrast to these changes throughout the rest of the hospital. This did not arise because there was evidence that ill infants needed to be isolated from their mothers for extended periods of time, or that they benefited from being in an open ward full of unnatural sensory stimuli. Nor was there evidence that caregivers, with the responsibility to recognize and respond to those sights and sounds that signaled impending danger for their patients, benefited from NICU design that was intended to be highly efficient, but which offered little respite from the cacophony of stimuli.

Even so, open units have certain advantages – one can see “everything and everyone,” which may have social and medical value. In this paper, we will explore ways in which the perceived advantages of open, ward-like units can be blended with environments that are individualized for the needs of each person in the

NICU – baby, parent, and caregiver – in ways that will be of demonstrable benefit to all.

**Hypothesis 1:** *The optimal “microenvironment” for a newborn infant, even (especially) one who is ill, is skin-to-skin with mother.*

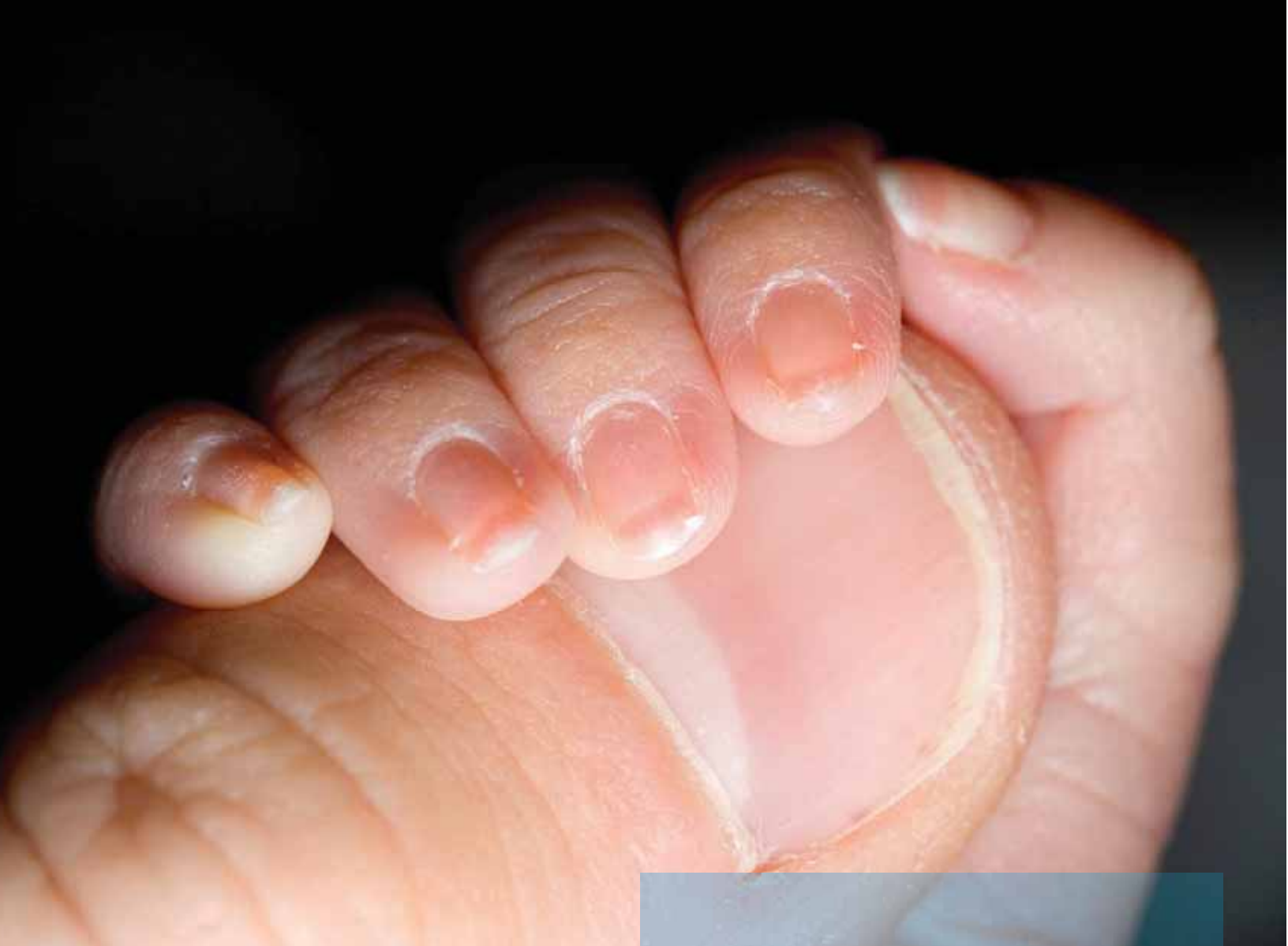The newborn’s brain is in the midst of an incredibly active period of growth and development during the third and “fourth trimesters.” Throughout this time, stimuli from the mother, both in and ex utero, are the biologically expected norm. From the pioneering work of Harlow through concerns expressed early in the history of intensive neonatal care<sup>1</sup> to recent RCT work<sup>2</sup>, a large body of evidence from the fields of medicine, psychology, sociology, and anthropology establishes that in altricial mammals, from rodents through primates to humans, smell, taste, touch, kinesthetic, and auditory stimuli (especially maternal) promote brain development, while deprivation of the same stimuli cause long-term deficits in the newborn. It has been relatively easy to ignore this evidence since much of it appeared in literature not often read by medical personnel, much of the human work was done in non-acute settings, and because the remarkable resilience of babies allowed us to believe they usually survived our profoundly unnatural NICU environment in relatively good shape.

Recently, though, several studies document the value of parental presence in general and specifically, in skin-to-skin (STS) care for NICU patients. Scher et al<sup>3</sup> demonstrated that STS accelerated EEG signs of brain maturation in preterm infants, while Milgrom et al<sup>4</sup> showed that training parents about the neurosensory needs of their babies enhanced white matter development. Fifer et al<sup>5</sup> have recently shown

**Do you or your colleagues have interesting research results, observations, human interest stories, reports of meetings, etc. that you would like to share with the neonatology community? Submit your proposed article to**

**[RichardK@Neonate.biz](mailto:RichardK@Neonate.biz)**

*The final manuscript may be between 400-4,000 words, and contain pictures, graphs, charts and tables.*



# Delivering patient care for more than 30 years



Pediatrix Medical Group recently reached another milestone in its history; its clinical data warehouse grew to more than 600,000 total patient outcomes, representing 12 million patient days. Drawing on this extensive data and collective experience, our neonatologists continue to work in a collaborative environment, exchanging ideas, introducing continuous quality improvement initiatives and launching clinical research studies on a national scale.

We thank our physicians for their ongoing dedication and unwavering commitment to improving patient care and advancing evidence-based medicine.

Please contact us to learn about neonatology positions in:

Oxnard, CA  
Macon, GA  
Lafayette, LA  
Reno, NV  
Harrisburg, PA

Chattanooga, TN  
San Antonio, TX  
Fredericksburg, VA  
Spokane, WA

800.243.3839, extension 6512  
[physician\\_recruit@pediatrix.com](mailto:physician_recruit@pediatrix.com)

*To learn more about positions available in other locations, please visit our Web site at [www.pediatrix.com/neojobstoday](http://www.pediatrix.com/neojobstoday).*

Pediatrix Medical Group is an Equal Opportunity Employer.

**Table 1: Private Rooms in the NICU reduce Length of Stay and BPD**

<30 Weeks Gestation	Open Unit	Private Rooms	
LOS, ICU	43.1 days	32.4 days	p=0.02
LOS, total	66.7 days	56.6 days	p=0.04
mod/severe BPD	6.0%	1.6%	OR 0.18 (0.4-0.8)

Adapted from Ortenstrand, et al, *Pediatrics* 125:e278-85, 20102.

that newborn infants learn to respond to an environmental stimulus even when asleep, emphasizing the continuous, intense nature of the learning process in newborns. These studies confirm a much larger body of work in animals that demonstrates how important the external environment, and especially parental interaction, is to the newborn.

**Hypothesis 2:** *The optimal “macroenvironment” for an ill newborn is a private room.*

Private rooms can reduce unwanted noise and light stimuli, increase parental interaction<sup>6</sup>, and lead to reduced length of stay and chronic lung disease<sup>2</sup> (Table 1). Concerns that safety might be compromised when infants are no longer in the direct line of sight of caregivers have been allayed in what are now dozens of private-room NICUs, as well as hundreds of pediatric and adult private-room ICUs. Open rooms with multiple patients cannot fully “insulate” babies from activity at adjacent bedsides, even with the best design.

Perhaps most important is the concept of individualized environments – the appropriate environment for a newly born 23-week infant is quite different from what will be optimal for that same infant 4 months later, or from what a full-term surgical infant might need. For example, in the latter two cases, the visual cortex is ready for external stimuli such as facial expressions, whereas the 23-weeker doesn’t even have blood supply to most of the retina. It is not possible in an open room design to accommodate the individual developmental needs of all of the babies all of the time, whereas this is much easier in a private room – a factor that is all the more important for babies who are not in STS contact with their mothers for extended periods of time.

**Hypothesis 3:** *The optimal setting for family involvement with an ill newborn is, in most instances, a private room.*

It is clear that most families prefer the private room setting. This is observed in before-and-after surveys, in patient satisfaction scores, and in units that have some beds in private rooms and some in open wards<sup>6</sup>. There are many reasons for this – families appreciate the privacy to bond with their infants, to receive unpleasant news, to ask questions of medical personnel, to “let their hair down.” They welcome the sense of ownership and family space that a private room provides. They benefit from not being exposed to crises at adjacent bedsides, and from the lowered noise and activity levels.

Yet not all situations are best handled in private rooms. Multiple births is an obvious example where the ability to care for two or more infants in a single room is advantageous. Nor do all families value privacy over community. Nils Bergman points out that in Africa, placing a baby and its family in a private room would be considered solitary confinement. Even in the US, some parents would prefer to be in an open room to increase their opportunities for interaction with other parents and caregivers.

**Hypothesis 4:** *The benefits of providing NICU care in a private room setting outweigh any perceived disadvantages for caregivers, and*

*most of the anticipated disadvantages can be overcome with good design.*

Universally, caregivers face the prospect of moving to a private-room NICU with trepidation. This is true even after talking with their colleagues in other private-room NICUs and in private-room pediatric and adult ICU facilities in their own institution. The greatest fear always relates to patient safety – even though we rely on monitors to alert us to problems the vast majority of the time, there is real comfort in being able to see the patients we are responsible for, and what is happening at their bedside.

Fortunately, electronic communication devices have progressed to the point where a nurse is never really out of contact with his/her patients, his/her colleagues, other support areas in the hospital, or the outside world – in fact, far more information is now available to the caregiver wherever he/she is. Challenges still exist; for example, alarms from devices that do not interface with the monitor system (e.g., ventilators, IV pumps) still must be transmitted in an auditory mode. Nevertheless, caregivers in units who have moved from open to private-room design are generally happy about the change<sup>7,8</sup>.

Other concerns about private-room design include a fear of isolation from colleagues, anticipation that travel distances for caregivers will be increased, and that staffing needs will increase. All of these are very real issues, but can be addressed with good design strategies.

One of the major benefits of private patient rooms is that it allows individualized environments for caregivers, too. In the past, caregivers, families, and patients all shared the same space, and most design and operational features were intended to make that environment optimal for babies. As a result, caregivers sacrificed their own needs to those of their patients – lights were turned down, radios turned off, conversations muted. Extensive literature on healthy workplaces has shown that access to daylight, bright lights at night, music, even pleasant scents create healthier, more pleasing environments for the workforce. When babies and their families have their own rooms, specific areas can be designed adjacent to but separate from patient rooms that have an environment optimal for the needs of caregivers.

#### *Design strategies for individualized environments in the NICU*

Single-family rooms (SFR) are the centerpiece of individualized environments for the NICU. They permit the optimal sensory macroenvironment for an ill newborn, and make STS care easier for parents. They provide individualized space for families, and also permit specialized areas to be developed for caregivers that do not encroach on the infant’s space.

The SFR must be large enough to meet the functions intended. There must be sufficient space around the bed (at least 4 feet clearance on either side and at the foot of the bed) for medical care to be provided, and enough room for a family member to provide STS care without interfering with equipment or storage areas at the bedside. In fact, the headwall should be designed so that it works well whether

the baby spends a majority of its time in STS care or in an incubator, warmer, or crib. A blueprint or mockup that shows only an infant bed in front of the headwall will almost certainly not be optimal for STS care, and will become a barrier to optimal care of the infant from day one.

SFR units are larger than comparable open-room units, so efficient care requires that most supplies that will be utilized on a regular basis are stored at the bedside, either in fixed or mobile (cart) devices. A sink and appropriate waste disposal containers must be present within each room; these are ideally located near the entrance to the room. Whether already part of the hospital's system or not, electronic medical records should be anticipated and a space allocated for a fixed or portable computer workstation.

The family space in the SFR should also be sufficient to permit parents to stay for extended periods in comfort. When these areas (patient care, caregiver support, and family) are adequately designed, the SFR will be at least 175 square feet, and could approach 300 square feet in an ideal setting.

In addition to the family space within the SFR, areas within the NICU should be allocated for parents to gather. Small, informal alcoves near patient rooms will be used more frequently and effectively than a large waiting room outside the main entrance of the NICU, especially if they provide daylight, coffee, and similar amenities for families under stress. Larger spaces outside of the patient care area can be dedicated to family support functions such as laundry, meals, education, and access to nature. This "staging" of family support from the SFR to areas within the NICU and then areas outside of the NICU allows families to choose the level of privacy or community they need at a given time.

Individualized environments for caregivers start in the patient room with an ergonomically-designed space away from but still near the immediate bedside for nurses to perform charting, consult with colleagues, or relax for a moment. Utilizing the same "staging" concept mentioned for families, additional areas for caregivers to gather should be provided in the center of a cluster of patient rooms, allowing caregivers to collaborate and socialize while still maintaining visual and electronic contact with their patients' rooms, and space outside of the pa-

tient care area for meals, access to nature, and other medical and non-medical activities that support an effective and satisfied team.

Many more factors go into optimal NICU design, of course, but are outside of the scope of this article. Excellent resources are readily available<sup>9-11</sup>.

### Closing thoughts

Perhaps the best way to illustrate the value of individualized environments is to recall our history with the use of breast milk and formula. For a time early in our specialty, there were suggestions that mother's milk was inappropriate for the feeding of preterm infants and that infant formulae were better options, partly because of their more desirable levels of protein and mineral intake, and partly because they were so much easier to store and deliver. Gradually, though, this trend was reversed as it became apparent that mother's milk was the best source of basic enteral nutrition for infants of any gestational age. Formulae have been improved to come closer to mother's milk, although even now after much research it is clear that we cannot deliver the rich diversity of nutrients, hormones, trace minerals, and other (some as yet undiscovered) bioactive substances through any medium other than mother's milk. The same is true for environmental stimuli. We can improve the NICU at large and incubators in particular to provide more suitable stimuli to infants, but they will never be better than a meager alternative to direct and extended contact with the mother, either in quality or quantity of all the sensory stimuli. Designing individualized environments for the NICU means, first of all, creating a culture where STS care is fostered, and then providing a space where the needs of each member of the NICU community can be met without encroaching on the needs of others.

### References

1. Brimblecombe FSW, Richards MPM, Robertson NRC: Separation and Special Care Baby Units. London, William Heinemann Medical Books Ltd., 1978.
2. Ortenstrand A, Westrup B, Brostrom EB et al: The Stockholm neonatal family centered care study: effects on length of stay and infant morbidity. *Pediatrics* 125:e278-85, 2010.
3. Scher MS, Ludington-Hoe S, Kaffashi, F et al: Neurophysiologic assessment of

brain maturation after an 8-week trial of skin-to-skin contact on preterm infants. *Clin Neurophysiol* 120:1812-8, 2009.

4. Milgrom J, Newnham C, Anderson P et al: Early sensitivity training for parents of preterm infants: impact on the developing brain. *Pediatr Res* 67:330-5, 2010.
5. Fifer WP, Byrd DL, Kaku M et al: Newborn infants learn during sleep. *Proc Nat Acad Science USA* 107:10320-3, 2010.
6. Carter BS, Carter A, Bennett S: Families' views upon experiencing change in the neonatal intensive care unit environment from the 'baby barn' to the private room. *J Perinatol* 28:827-9, 2008.
7. Stevens DC, Helseth CC, Khan MA et al: Neonatal intensive care nursery staff perceive enhanced workplace quality with the single-family room design. *J Perinatol* 30:352-8, 2010.
8. Smith TJ, Schoenbeck K, Clayton S: Staff perceptions of work quality of a neonatal intensive care unit before and after transition from an open bay to a private room design. *Work* 33:211-27, 2009.
9. White RD (ed.): The Sensory Environment of the NICU: Scientific and Design-related Aspects. *Clinics in Perinatology* 31(2), Philadelphia, PA, WB Saunders, 2004.
10. White, RD, et al: Recommended Standards for the Newborn ICU. *J Perinatol* 27:S4-19, 2007.
11. Institute for Patient and Family-Centered Care: <http://www.ipfcc.org>.

NT



Robert White, MD  
Pediatrix Medical Group of Indiana  
Memorial Hospital  
615 N. Michigan St.  
South Bend, IN 46601  
Tel: 574-647-7351

email: [Robert\\_White@pediatrix.com](mailto:Robert_White@pediatrix.com)

## The 24th Annual Gravens Conference on the Physical and Developmental Environment of the High Risk Infant, In collaboration with the March of Dimes

January 26-29, 2011

Sheraton Sand Key ❖ Clearwater Beach, FL

[www.cme.hsc.usf.edu](http://www.cme.hsc.usf.edu)

[brose@health.usf.edu](mailto:brose@health.usf.edu)



# Global Neonatology Today: A Monthly Column

By Dharmapuri Vidyasagar, MD, FAAP, FCCM

## MILLENNIUM DEVELOPMENT GOAL (MDG #6)

The goal of MDG #6 is to combat HIV/AIDS, Malaria and other diseases, particularly Tuberculosis.

### THE TARGETS

- To halt HIV/AIDS and begin to reverse the spread of HIV/AIDS by 2015.
- To achieve universal access to treatment of HIV/AIDS for all those who need it by 2010.
- To halt and begin to reverse the incidence of malaria and other major diseases by 2015.

In this review we will address the status of the Goal of combating HIV/AIDS only. Next month, we will continue the review of MDG #6 focusing on Malaria and other diseases.

### THE INDICATORS

The indicators used to measure the success of prevention of HIV/AIDS are:

1. HIV prevalence among women - 15-24 years.
2. Condom use rate of the contraceptive prevalence rate.
3. Knowledge of HIV/AIDS among 15-24 year old.

### THE PROGRESS MADE

#### Target

As noted above the target is to halt and begin to reverse the spread of HIV/AIDS by 2015. The latest information shows that globally the spread of HIV peaked in 1996 when an estimated 3.5 million people were newly infected. By 2008 the infection dropped to estimated 2.7 million. AIDS related mortality dropped from 2.2 million in 2004 to 2 million in 2008. However, AIDS is still the major cause of death in the world today.

Thus, the spread of HIV appears to have stabilized, and deaths from AIDS has decreased. People with AIDS are living longer due to life sustaining treatments although there are wide regional differences:

- In 2008, an estimated 33 million were living with HIV: 22 million of which were in sub-Saharan Africa.
- In 2008, Sub-Saharan Africa accounted for 72% of all new HIV infections.
- Prevalence of AIDS continues to rise in Eastern Europe, Central Asia and as well as other parts of Asia.
- Prevention is the first step to curb HIV infection.

Though some progress has been made, comprehensive and well-informed knowledge of HIV among young people is still unacceptably low in most countries. Less than one third of young men, and less than one fifth of young women in developing countries claim such knowledge about HIV. According to surveys undertaken between 2003 and 2008, the lowest levels (8%) are found among young women in Northern Af-

rica. These levels are well below the 2010 target of 95% set at the United Nations General Assembly Special Session on HIV/AIDS in 2001.

---

***“In summary, the Goal of MDG #6 in relation to prevention of HIV/AIDS is being met steadily. However, wide regional, gender differences exist. Populations in sub-Saharan Africa, and women and children in general, continue to bear the brunt of the disease in many ways.”***

---

In spite of various new treatment modalities, for every two individuals treated, five are newly infected. Thus, there is a greater need for prevention and treatment. Increasing numbers of people are being treated every year. Forty-two percent in 2008 compared to 33% in 2007 of those needing treatment, got treatment.

Children also are taking a major brunt of HIV/AIDS. In addition to mother to infant transmission of disease, children orphaned by AIDS suffer more than the loss of parents. Estimated 17.5 million (<18 yr.) lost one or both parents to AIDS in 2008.

In summary, the goal of MDG #6 in relation to prevention of HIV/AIDS is being met steadily. However, wide regional and gender differences exist. Populations in sub-Saharan Africa, and women and children in general, continue to bear the brunt of the disease in many ways. There is a lot more work to be done to meet the targets of HIV/AIDS-related targets of MDG #6.

For more information:

[http://who.int/topics/millennium\\_development\\_goals/diseases/en/index.html](http://who.int/topics/millennium_development_goals/diseases/en/index.html)

### The Clock is Ticking!

NT



Dharmapuri Vidyasagar, MD, FAAP, FCCM  
University of Illinois at Chicago  
Professor Emeritus Pediatrics  
Division of Neonatology  
Phone: +1.312.996.4185; Fax: +1.312.413.7901

[dvsagarmd@yahoo.com](mailto:dvsagarmd@yahoo.com)

## The 6th International Conference on Brain Monitoring and Neuroprotection in the Newborn

February 10-12, 2011

The Krasnapolsky ❖ Amsterdam, The Netherlands  
[www.cme.hsc.usf.edu](http://www.cme.hsc.usf.edu)      [brose@health.usf.edu](mailto:brose@health.usf.edu)



# Subgaleal Hemorrhage Following Vacuum Extraction Vaginal Delivery: A Frequently Undiagnosed Problem

By Houchang D. Modanlou, MD

## Background

At term gestation, in a nullipara woman, during the second stage of labor, for a duration of approximately one hour, vacuum extractor was used 9 times with several pup-offs. The obstetrician failed and resorted to forceps application for the delivery of a 3465 g male infant. Reasons for the application of vacuum extractor were noted to be non-reassuring fetal heart rate tracings and maternal exhaustion. At delivery, the infant was noted to be pale, flaccid without any heart beat or respiratory efforts. Appropriate resuscitation was initiated following NRP guidelines. Apgar scores of 0, 0, 3, and 7 were assigned for 1, 5, 10 and 15 minutes of life, respectively. Prior to the transport of the infant to a tertiary unit at a Children's hospital for whole body cooling, a physical examination in the NICU, revealed significant head molding and the description of a large and fluctuating head mass written as caput succedaneum. At the Children's Hospital, both the receiving pediatric resident and the neonatal fellow described failed vacuum applications of six times, a "boggy" head again written as a large caput succedaneum. A working diagnosis of hypoxic-ischemic encephalopathy (HIE) was entertained and whole body cooling was initiated, based on a nationally accepted protocol. After 72 hours, whole body cooling was discontinued and detailed neurological evaluation was carried out with EEG recordings and brain MRI. EEG was reported to be very abnormal and MRI showed changes related to HIE but without intracranial hemorrhage and the presence of extracranial fluid collection. Despite maximum efforts, the team of pediatric neurologist and neonatologist noted that infant's neurological condition was grave and not reversible. After parental counseling, it was decided to provide only palliative care. The infant eventually expired at 36 day of life. An autopsy was performed. Findings were consistent with the primary clinical diagnosis of HIE. Additionally, a large sero-sanguinous fluid collection was noted below the scalp aponeurosis with patchy calcification above the periosteum.

Although during the entire hospitalization both nursing and the medical staff repeatedly noted the "boggy" scalp, as well as the MRI report noted extra cranial fluid collection, it was referred to as resolving caput succedaneum. No diagnosis of subgaleal hemorrhage (SGH) was recorded descriptively or as a diagnosis. It should be noted that the infant's hematocrit (HCT) prior to transport was recorded to be 55.7%. By 24 hours of life, the HCT was recorded to be 31%. At that point packed RBC

transfusion was carried out without explanation for a clinically significant drop in HCT.

This case clearly illustrates a lack of knowledge and/or experience of some of our pediatricians and neonatologists in the community hospitals as well as the pediatric residents and fellows in-training and neonatologists in the academic medical centers regarding the potential neonatal complications associated with inappropriate application of vacuum extractor to effect delivery. For the past three decades the use of vacuum extractor has significantly increased in the United States. Indeed, its application has surpassed the use of obstetrical forceps.

Subgaleal hemorrhage post vacuum extraction delivery may be of a rare occurrence, however, it may not be well apparent soon after birth but it may progress to become massive hemorrhage and at times fatal. Pediatric medical staff may not be familiar with potential complication associated with vacuum extraction delivery. Here, a description of vacuum, its application, and its potential neonatal complication is provided with the hope that more attention is paid to its complications. Recognition of a clinically significant SGH and the institution of an early treatment may lessen neonatal morbidity and mortality.

## Modern Vacuum Extractors

Over the past three decades, vacuum extractor has progressively replaced forceps as the delivery instrument of choice for many obstetricians.

The vacuum extractor consists of three main parts: a cup that is designed to fit snugly against the top of the baby's head, a suction device that is capable of generating negative pressure, and plastic tubing that connects the cup to the suction device.

Current vacuum instruments used in obstetrical practice are based on the original design by Malmstrom in 1950's<sup>1,2</sup>. Malmstrom's metal cup is a hollow hemisphere with incurved margins, designed to be filled with artificial caput succedaneum. A traction chain is passed through suction tubing, which is attached to a short metal pipe at the dome of the cup, and a hand-pump is connected through a suction bottle. The suction induces an artificial caput succedaneum or chignon within the cup to which a traction force is applied in concert with uterine contractions. In the early 1970's, a soft vacuum cup was introduced with several modifications. Currently, available soft vacuums are made of soft rubber, rigid plastic, soft silicone, and rigid or soft polyethylene (Figure 1). These

are manually or electronically operated<sup>3</sup>. Both types of suction devices are equipped with gauges that monitor the amount of pressure being generated. Release valves allow rapid disengagement of the pressure as needed.

These soft vacuum extractors have become the predominant instrument used for operative vaginal delivery in the United States<sup>4</sup>. When compared with metal cup, soft cups are significantly more likely to fail to achieve vaginal delivery however; they were associated with less neonatal scalp injury<sup>5</sup>. A list of modern vacuum devices can be found in a recent publication by Ali and Norwitz<sup>6</sup>.

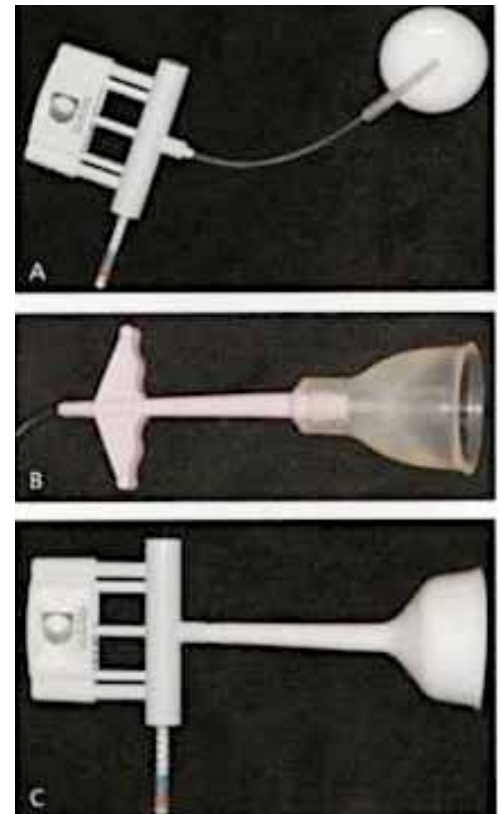


Figure 1. Some examples of modern vacuum extractors: A. The Kiwi Omnicup; B. Soft vacuum hand-pump suction by an assistant; and C. Single handheld vacuum with operator hand-pump suction.

## Indication for Vacuum Application

In the United States, 5 to 10% of all vaginal deliveries are operative and are accomplished with the use of vacuum and/or forceps<sup>6,7</sup>. The rate of operative deliveries in some centers in Europe is ranging from 5.3 to 34.1% of all births<sup>8</sup>. Use of the vacuum for operative vaginal deliveries has become more favorable.

During the past decade the number of vacuum deliveries overtook the number of forceps deliveries performed<sup>9, 10</sup>. When compared with forceps-assisted deliveries, the vacuum has been associated with a higher incidence of neonatal complication and NICU admissions<sup>11</sup>. Operative vaginal delivery remains a valid option when problems arise in the second stage of labor. The most common indications are fetal compromise and failure to deliver spontaneously with maximum maternal efforts<sup>12</sup>. The Royal College of Australian and New Zealand of Obstetricians and Gynaecologists gives two indications for operative vaginal deliveries: one, fetal compromise suspected or anticipated; two, delay in the second stage of labor<sup>13</sup>. Similarly, the American College of Obstetricians and Gynecologists (ACOG) has published guidelines for the indications of vacuum use for maternal and fetal reasons<sup>14,15</sup>. Furthermore, ACOG made recommendations regarding the fetal contraindication for vacuum use as well as the application of cup pressure, traction, pressure release and discontinuation of its application based on cup dislodgements, lack of progress and duration of its use. The goal of operative vaginal delivery is to mimic spontaneous vaginal birth, thereby expediting delivery with a minimum of maternal or neonatal morbidity<sup>16</sup>.

### Neonatal Complications

The most consistent finding post-vacuum extraction delivery is the presence of caput succedaneum created by the suction pressure of the vacuum called chignon or exaggerated larger lesion with ecchymosis of the scalp tissue. In either case, the lesion is due to exudation of fluid and, at times, extravasations of blood into scalp tissue. The edema is soft, superficial, and pitting in nature, and crosses sites of suture lines<sup>17, 18</sup>. Generally, the scalp edema resolves by 24 hours however, the resolution of the ecchymosis will take a few days.

Other neonatal complications post vacuum-assisted delivery are: scalp lacerations, subgaleal hemorrhage (SGH), cephalohematoma, skull fracture, intracranial hemorrhage, subconjunctival and retinal bleeding, shoulder dystocia, and neonatal hyperbilirubinemia as the result of extravasated blood. On rare occasion fetal and neonatal deaths have been reported<sup>19, 20, and 21</sup>. During the period of 1994 and 1998, FDA identified 12 deaths and 9 serious complications following vacuum-assisted vaginal deliveries<sup>19</sup>. The FDA cautioned and provided recommendations to healthcare providers about the use of vacuum extractors. It stressed also the importance of notifying pediatricians that a vacuum device was used to effect delivery and the neonate to be monitored more closely for the first hours and days of life. During a 6 months period post-FDA advisory, Ross et al<sup>22</sup> reported 10 neonatal deaths and several serious neonatal injuries after vacuum-assisted deliveries.

### Subgaleal Hemorrhage

Scalp tissue may detach from the skull bone due to the effects of the applied suction or by the tangential shearing of the scalp from the skull. The former is more common with excessive negative cup pressure and/or traction or when the vacuum extractor cup is applied above the anterior fontanel. The latter may occur with tangential pulling of the hair or combing of the hair in a hemophilic patient<sup>23, 24</sup>. Subgaleal hemorrhage occurs when emissary veins bridging the subgaleal space are damaged and blood accumulates in the potential space between the galea aponeurotica (epicranial aponeurosis) and the periosteum of the skull bones (pericranium). Since the subaponeurotic space has no containing membranes or boundaries, the SGH may extend from the orbital ridges to the nape of the neck. This condition is dangerous because of the large potential space for blood accumulation with a volume of several hundred milliliters<sup>25</sup>. This blood loss can produce profound hypovolemic shock, disseminated intravascular coagulation (DIC), unresponsive metabolic acidosis and death. The hemorrhage in the subgaleal space is not instantaneous but is gradual and it may not be apparent or diagnosed at the time of delivery or at the initial neonatal examination during the first few hours of life. It may not become clinically apparent until several hours or up to a few days following delivery.

Based on our experience, SGH may be initially confused with large caput succedaneum or cephalohematoma. Although a caput succedaneum, which is made of edema and transudation into the dermis, is commonly present with a SGH, not surprisingly, the descriptions of caput succedaneum and its graphical presentations in the leading textbooks of neonatology<sup>26, 27</sup> and in the recent review article in the obstetrical literature<sup>6</sup> are not very accurate. One textbook of neonatology<sup>26</sup> describes "serum or blood or both accumulate above the periosteum in the presenting part during labor" while another textbook<sup>27</sup> and the review article<sup>6</sup> show hemorrhage associated with caput succedaneum below aponeurosis. Above periosteum and below aponeurosis is the subgaleal space. Any hemorrhage in this space is SGH and not caput succedaneum.

The edema of caput succedaneum should regress by the first 24 hours of life although the scalp ecchymosis will persist for a few days. Cephalohematoma, on the other hand, is a subperiosteal hemorrhage, which may not be apparent at the time of delivery. Initially it is tense in consistency and is limited to the individual skull bone with which it is associated and does not cross the midline. Within 24 hours the lesion becomes soft and in a few days one can palpate the calcified margin of the lesion. A persistent fluctuating and boggy scalp lesion, crossing the suture lines, persisting after 24 hours of life should suggest the diagnosis of SGH. The

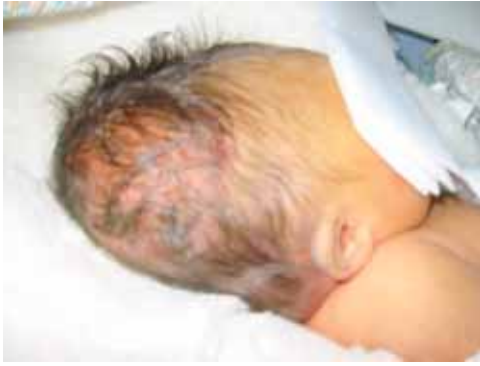head will appear elongated (Figure 2) with considerable molding of the skull bones. The lesion is fluctuating and gives the sensation of an old leather pouch filled with fluid. The fluid will be gravity dependent and accumulates on the dependent aspects of the head. In severe cases of massive SGH, there can be elevation and displacement of the ear lobes and puffiness of the eyelids without superficial ecchymosis of the overlying skin. Massive SGH is frequently associated with hypovolemic shock, DIC, persistent metabolic acidosis and death. Associated findings are low Apgar scores, pallor, tachycardia, increased respiratory rate, hypotension and neonatal anemia<sup>21</sup>.

### Diagnosis and Management

The occurrence of SGH after vacuum extraction ranges from 26 to 45 per 1000 vaginal deliveries<sup>15</sup>. The lesion may not be apparent at birth<sup>21</sup>. In a prospective observational cohort study Smit-Wu et al.<sup>28</sup> found that vacuum extraction SGH occurred in term neonates within 10 hours following birth. I believe that SGH occurs more frequently than is reported in the obstetrics and pediatric literature. This is most likely due to failure of diagnosis, partly because of its association with intracranial hemorrhage. Lack of experience of the pediatric residents, neonatal fellows, pediatricians and the neonatologists is due to their limited time in neonatal care and delivery room attendance during their training may be another reason for failure to diagnose SGH.

In a recent article about pediatricians and the law in the AAP News, Goldsmith stated that general pediatricians face increased scrutiny in the newborn nursery. He enumerated the areas of concern to which pediatricians should pay attention. He listed communication issues with parents, attendance at deliveries/resuscitation, jaundice, genetic screening, GBS testing, and missed diagnosis. What Goldsmith did not mention in his commentary is the lack of knowledge about obstetrical history, particularly problems related to labor and delivery and the instrumentations to effect delivery, that pediatricians, pediatric residents, neonatal fellows and the neonatologists or whoever presents himself/herself in the delivery room or to the newborn nursery have. In the rush of attending to the delivery of a distressed newborn, important information may not be verbally communicated between the obstetrical healthcare providers and the neonatal team. With the electronic medical records, the pediatric healthcare providers may not have access to important obstetrical history. Knowledge of an accurate obstetrical history, particularly of the labor and delivery process, is paramount for the pediatric healthcare providers to make correct diagnosis and anticipate possible problems in the newborn.

Subgaleal hemorrhage, as the result of an inappropriate use of vacuum extraction deliv-



*Figure 5. This is a picture of a 3-day-old term newborn infant following vacuum extraction delivery at a community hospital. Vacuum was applied 6 times with several pop-offs. Note generalized jaundice and elongated head with the evidence of gravity dependent extra cranial fluid. At the time of admission to our NICU, 6 hours of life, infant's Hematocrit was 31%. Transfusion of packed RBCs, 15 ml/Kg, was carried out soon after admission. There was neither blood group incompatibility nor intracranial hemorrhage. At 4 years of age, the child is healthy. (Written signed permission from the child parents was obtained).*

ery, is associated with significant neonatal morbidity and mortality. Early recognition of SGH and the institution of supportive care such as blood transfusion, volume support, and coagulation factors, in the presence of DIC, are useful and indicated. Palliative treatment such as head wrapping has limited value. Early recognition and treatment of SGH is critical. Serial observations for neonatal scalp changes, as described above, signs of pallor, anemia, metabolic acidosis and hypovolemia are recommended after vacuum-assisted deliveries.

### Summary

The clinical feature of SGH is described in order to help the reader to be vigilant about the rare occurrence of this serious complication with the application of vacuum extractor. The obstetrician should inform the neonatal healthcare providers that a vacuum extractor was used to effect delivery. Neonatal staff should be educated about the correct anatomy and the specific neonatal complications associated with vacuum devices. Neonatal healthcare personnel should evaluate the infant frequently in order to timely diagnose and institute appropriate therapy in order to avoid serious morbidity and/or neonatal death.

### References

1. Malmstrom T. Vacuum Extractor-An Obstetrical Instrument. Gothenberg, Sweden: Northern Association of Obstetrics and Gynaecologists 1954, pp 1-32.

2. Malmstrom T. The vacuum extractor: an obstetrical instrument. *Acta Obstet Gynecol Scand.* 1957; 36:5-49.
3. Mikovsky P, Watson WJ. Obstetric vacuum extraction: state of the art in the new millennium. *Obstet Gynecol Surv* 2001; 56:736-51.
4. Curtin SC, Park MM. Trends in the attendant, place and timing of births, and the use of obstetric interventions; United States, 1989-97. *Natl Vital Stat Rep* 1999; 47:1-12.
5. Johanson R, Menon V. Soft versus rigid vacuum extractor cups for assisted vaginal delivery. *Cochrane Database of Systematic Reviews* 2000, Issue 2. Art. No.: CD000446. DOI: 10.1002/14651858.CD000446.
6. Ali UA, Norwitz ER. Vacuum-Assisted Vaginal Delivery. *Rev Obstet Gynecol.* 2009; 2(1): 5-17.
7. Bofill JA, Rust OA, Perry KG Jr, Roberts WE, Martin RW, Morrison JC. Forceps and vacuum delivery: a survey of North American residency programs. *Obstet Gynecol.* 1996 Oct; 88(4 Pt 1): 622-5.
8. Mangin M, Ramanah R, Aouar Z, Courtois L, Collin A, Cossa S, Martin A, Maillet R, Riethmuller D. Operative delivery data in France for 2007: results of a national survey within teaching hospitals. *J Gynecol Obstet Biol Reprod (Paris).* 2010 Apr; 39(2): 121-32.
9. McQuivey RW. Vacuum-assisted delivery: a review. *J Matern Fetal Neonatal Med.* 2004 Sep; 16(3): 171-80.
10. Putta LV and Spencer JP. Assisted Vaginal Delivery Using the Vacuum Extractor. *AM Fam Physician* 2000; 62:1316-20.
11. Kicklighter SD, Wolfe D, Perciaccante JV. Subgaleal hemorrhage with dural tear and parietal-lobe herniation in association with a vacuum extraction. *J Perinatol.* 2007 Dec; 27(12):797-9.
12. Yeomans ER. Operative vaginal delivery. *Obstet Gynecol.* 2010 Mar; 115(3):645-53
13. The Royal College of Australian and New Zealand of Obstetricians and Gynaecologists, College Statement, C-Obs 16, November 2009.
14. American College of Obstetricians and Gynecologists. Delivery by vacuum extraction. Washington, DC: ACOG Committee on Obstetric Practice. Committee Opinion. Number 208, September 1998.
15. American College of Obstetricians and Gynecologists. Operative vaginal delivery. Washington, DC: ACOG; 2000. Practice Bulletin No 17.
16. Royal College of Obstetricians and Gynaecologists (RCOG). Operative vaginal delivery. London (UK): Royal College of Obstetricians and Gynaecologists (RCOG); 2005 Oct. 13 p. (Guideline; no. 26).
17. Potter EL, Craig JM. Pathology of the Fetus & the Infant. Third Edition, 1975, page 104. Year Book Medical Publishers, Inc., Chicago.
18. Volpe JJ, Neurology of the Newborn. Third Edition, 1995, Page 769, W.B. Saunders Company, Philadelphia.
19. Center for Devices and Radiological Health. FDA Public Health Advisory: Need for CAUTION when using vacuum assisted delivery devices. May 21, 1988.
20. F Gary Cunningham et al., Editors. Williams Obstetrics. Chapter 21: Forceps delivery and vacuum extraction. 21st Edition, Mc Graw Hill, New York, 2001.
21. Modanlou HD. Neonatal Subgaleal hemorrhage Following Vacuum Extraction Delivery. *The Internet Journal of Pediatrics and Neonatology.* 2005; Volume 5, Number 2.
22. Ross MG, Fresquez M, El-Haddad MA. Impact of FDA advisory on reported vacuum-assisted delivery and morbidity. *J Matern Fetal Med.* 2000; 9: 321-326.
23. Hamlin H. Subgaleal hematoma caused by hair-pull. *JAMA.* 1968 Jul 29; 205(5):314.
24. Falvo CE, San Filippo JA, Vartany A, Osborn EH. Subgaleal hematoma from hair combing. *Pediatrics.* 1981 Oct; 68(4): 583-4.
25. Mikovsky P, Watson WJ. Obstetric vacuum extraction: state of the art in the new millennium. *Obstet Gynecol Surv* 2001;56:736-51.
26. Mangurten HH. Birth Injuries, in Martin RJ, Fanaroff AA, and Walsh MC. Editors. Fanaroff and Martin's Neonatal-Perinatal Medicine, Diseases of the Fetus and Infant. 8th Edition, 2006, Volume One, Chapter 27, page 531. Mosby Elsevier, Philadelphia.
27. Menkes JH. Perinatal Central Nervous System Asphyxia and Trauma. In Taeusch, Ballard, and Avery, Editors Schaffer & Avery's Diseases of the Newborn, Sixth Edition, 1991, page 407. W.B. Saunders Company, Philadelphia.
28. Smit-Wu MN, Moonen-Delarue DM, Benders MJ, Brussel W, Zondervan H, Brus F. Onset of vacuum-related complaints in neonates. *Eur J Pediatr.* 2006 Jun; 165(6):374-9.
29. Goldsmith JP. Pediatricians and the Law... General pediatrics face increased scrutiny in newborn nursery. *AAP News*, Volume 31, Number 6, June 2010.



*Houchang D. Modanlou, MD  
University of California, Irvine*

*Address:  
11 Shoreview  
Newport Coast, CA 92657 USA  
modanlou@uci.edu*



# Medical News, Products and Information

## Use of 3D MRI is Helpful Tool for Displaying Fetal Anatomy

Three-dimensional MRI is an emerging and useful technique for displaying fetal anatomy and diagnosing problems in the womb in a wide spectrum of clinical applications, according to Jeffrey C. Hellinger, MD, a pediatric imaging specialist at SBUMC (Stony Brook University Medical Center).

"Through enhanced visualization, 3D MRI improves one's understanding and ability to display fetal anatomy. With a better understanding and display of anatomy, it enhances exam interpretation and communication," said Dr. Hellinger, who details the uses and advantages of the technique in "Fetal MRI in the Third Dimension," a review published in the July-August issue of *Applied Radiology*, the journal for radiologists, and available online.

"I joined Stony Brook to help advance pediatric imaging, beginning with select imaging protocols, and this is one of them," said Dr. Hellinger, who came to SBUMC around the June 2010 launch of Stony Brook Long Island Children's Hospital, the only dedicated children's hospital east of the Nassau/Queens border.

Stuart E. Mirvis, MD, Editor-in-Chief of *Applied Radiology*, comments on the piece, writing "Our cover story this month is quite likely the first article of its kind. It is an excellent review of 3D Fetal MRI techniques...The article does more than illustrate several flashy pictures that can be generated on 3D workstations and instead shows clinical radiologists, who may not be as familiar with this technology, that not only can it be done, but there are very beneficial emerging applications."

Three-D sequences, which are available with fetal MRI at SBUMC, has distinct advantages for the pregnant mother, Dr. Hellinger points out. Because the fetus is moving frequently during a typical 20-24 week exam, 2D MRI necessitates obtaining multiple images in multiple planes. "That translates to a fairly long exam, an average of 30 minutes to 45 minutes. For any patient an MRI can be discomfoting, let alone someone who is pregnant."

With a 3D MRI, a practitioner can obtain volumetric, high resolution images that can be manipulated to view in any plane desired, obviating the need for redundant 2D images and potentially decreasing the overall exam time. "With the right image quality, that means less time in the magnet for the mom, improving workflow, and improving patient satisfaction," he explained.

Ultrasound and the newer 3D ultrasound remains the "principle obstetrical imaging modality. It is readily performed in outpatient and inpatient settings at minimal inconvenience to the mother, yielding reliable information for immediate clinical counseling and management," Dr. Hellinger writes in the *Applied Radiology* article. However, Dr. Hellinger writes that MRI "offers superior spatial resolution and structural detail, affording comprehensive anatomical displays from single acquisitions."

"MRI is often requested to provide more definitive anatomical understanding and diagnosis for abnormalities identified on the screening ultrasound, as well as to assess for concomitant abnormalities. The literature has also advocated its use for anatomical screening in the setting of congenital heart disease and predisposed families."

The 3D MRI has numerous uses at SBUMC for pediatric imaging. Physicians practicing in various subspecialties, such as Maternal-Fetal Medicine, Pediatric Cardiology, and Pediatric Pulmonology, Allergy and Immunology, are beginning to use the imaging modality.

"Ultrasound serves as the standard test to evaluate non-cardiac fetal anatomy, and MRI imaging for fetal, placental, and uterine abnormalities can be useful in confirming or clarifying possible abnormalities that ultrasound detects. But because of our inability to control fetal movement in utero, the shorter time taken to get 3D MRI images of fetuses gives us a better chance of getting useful fetal images than standard 2D MRI," says Paul, Ogburn, MD, Director, Maternal-Fetal Medicine.

"Three-D imaging can act as an adjunct to add to our understanding of congenital heart defects and also of any other congenital abnormalities that may be present in the

fetus," says Laurie Panesar, MD, Assistant Professor of Pediatrics in the Division of Pediatric Cardiology. "By detecting these types of problems prenatally, we can better prepare for the baby's birth and also better prepare the parents about what to expect when their baby is born."

Thomas Biancaniello, MD, Chief of Pediatric Cardiology, adds that 3D MRI is beneficial for imaging the fetus because "the diagnostician may have little control of the views obtained by fetal echocardiography because of the fetal position."

"Three-D MRI has been shown to be useful in infants, older children, and teenagers with congenital heart disease, as it allows visualization of structures that are out of the range of more conventional imaging," he explains.

According to Catherine Kier, MD, Chief of Pediatric Pulmonology, Allergy and Immunology, and Director, Cystic Fibrosis Center, 3D MRI plays into the importance of early diagnosis, which is critical regarding long-term pediatric patient outcomes.

"Congenital pulmonary abnormalities like diaphragmatic hernia and cystic lung lesions can be diagnosed with state-of-the-art fetal imaging like 3D MRI. This in combination with subspecialty collaboration and comprehensive services will lead to excellent patient outcomes."

Dr. Hellinger's article contains striking fetal images taken with 3D MRI. He and co-author Monica Epelman, MD, of the Department of Radiology at The Children's Hospital of Pennsylvania, conclude the article on 3D fetal MRI stating, "Successful utilization requires optimized image quality and understanding of advanced visualization techniques. Continued evidence-based investigation is required to determine the impact of 3-dimensional fetal MRI on fetal diagnosis and management."

## Prenatal Pesticide Exposures Linked to Attention Disorders in Preschool Children

Exposure to organophosphate (OP) pesticides before birth can increase susceptibility to attention disorders such as attention deficit/



## Contemporary Management of Neonatal Pulmonary Disorders Conference

November 4-5, 2010; Tempe Mission Palms, Tempe, Arizona

Contact: Cathy Martinez (602) 277-4161 x 11 ■ Fax: (602) 265-2011 ■ E-mail: [cathy@nalweb.com](mailto:cathy@nalweb.com)

[www.nalweb.com/cmnpdconference](http://www.nalweb.com/cmnpdconference)

hyperactivity disorder (ADHD), according to new research published in the journal *Environmental Health Perspectives* (EHP). The new study is part of a growing body of research indicating that exposure to OP pesticides can adversely affect brain development.

OP pesticides target the nervous systems of insects by affecting the activity of neurotransmitters including acetylcholine, which in humans plays a critical role in brain development and is involved in attention and short-term memory. Exposure to OP compounds may also disrupt DNA replication and the growth of nerve axons and dendrites. Infants and young children are much more vulnerable to OP exposures than adults are because their ability to produce the enzyme that detoxifies OP pesticides is still developing.

Mothers participating in the study were recruited during pregnancy by the Center for the Health Assessment of Mothers and Children of Salinas (CHAMACOS). The Mexican-American women lived in the Salinas Valley, an area of intensive agriculture where more than 235,000 kg of pesticides are applied annually. The researchers analyzed six OP metabolites in urine samples collected from the mothers during pregnancy and from their children several times after birth. The presence of these metabolites indicated exposure to OP pesticides used in the Salinas Valley, such as chlorpyrifos, diazinon, and oxydemeton-methyl.

The children's behavior was assessed at the ages of 3 and a half years ( $n = 331$ ) and 5 years ( $n = 323$ ) using reports from the mothers and standardized psychological tests.

The results indicated that as the concentration of OP metabolites in the urine of pregnant women increased, so did the likelihood that their children's test scores would be consistent with a clinical diagnosis of ADHD. The association was stronger at age 5 years than at 3 and a half and was more pronounced in boys than in girls. Prenatal exposures had a greater association than did exposures after birth: A tenfold increase in levels of measured pesticide metabolites in the mother's urine during pregnancy correlated to about a 500% increase in the likelihood of attention issues in their 5-year-olds; whereas, a tenfold increase in levels of metabolites in the children's urine at 5 years of age corresponded to a 30% higher likelihood.

By measuring prenatal exposures and focusing on participants likely to have higher exposures to OP pesticides than the general population, this study complements research published in the June 2010 issue of the journal *Pediatrics*. In that study, Maryse Bouchard and colleagues measured the same six OP metabolites in 1,139 children aged 8 to 15 years selected from the general US population. They found associations between OP exposure and ADHD even though those children had lower average exposures than did the children in the CHAMACOS study.

The authors of the EHP study suggest that research should continue to investigate whether genetic differences in OP metabolism affect susceptibility to developmental disorders, including ADHD. They state that "given that attention problems of children interfere with learning and social development, finding potential causes that can be remediated are of great public health importance." A companion article, also released today in EHP, explores potential genetic mechanisms behind effects associated with OP exposure.

The authors of "Organophosphate Pesticide Exposure and Attention in Young Mexican-American Children" are Amy R. Marks, Kim Harley, Asa Bradman, Katherine Kogut, Dana Boyd Barr, Caroline Johnson, Norma Calderon, and Brenda Eskenazi. This research was funded by grants from the National Institute of Environmental Health Sciences, the US Environmental Protection Agency, and the National Institute for Occupational Health and Safety. The article is available at <http://ehponline.org/article/info:doi/10.1289/ehp.1002056>.

The authors of the companion paper, "PON1 and Neurodevelopment in Children Exposed to Organophosphate Pesticides in Utero," are Brenda Eskenazi, Karen Huen, Amy Marks, Kim G. Harley, Asa Bradman, Dana Boyd Barr, and Nina Holland. This research was funded by grants from the National Institute of Environmental Health Sciences and the US Environmental Protection Agency. The article is available at <http://ehponline.org/article/info:doi/10.1289/ehp.1002234>.

EHP is published by the National Institute of Environmental Health Sciences, National Institutes of Health, US Department of

Health and Human Services. EHP is an open-access journal, and all EHP content is available free online at [www.ehponline.org](http://www.ehponline.org).

Source: *Environmental Health Perspectives* (NIEHS)

## NEONATOLOGY TODAY

© 2010 by Neonatology Today  
ISSN: 1932-7129 (print); 1932-7137 (online).  
Published monthly. All rights reserved.

### Publishing Management

Tony Carlson, Founder & Senior Editor  
[TCarlsonmd@gmail.com](mailto:TCarlsonmd@gmail.com)  
Richard Koulbanis, Publisher & Editor-in-Chief  
[RichardK@Neonate.biz](mailto:RichardK@Neonate.biz)  
John W. Moore, MD, MPH, Medical Editor/  
Editorial Board  
[JMoore@RCHSD.org](mailto:JMoore@RCHSD.org)

**Editorial Board:** Dilip R. Bhatt, MD; Barry D. Chandler, MD; Anthony C. Chang, MD; K. K. Diwakar, MD; Philippe S. Friedlich, MD; Lucky Jain, MD; Patrick McNamara, MD; David A. Munson, MD; Michael A. Posencheg, MD; DeWayne Pursley, MD, MPH; Joseph Schulman, MD, MS; Alan R. Spitzer, MD; Dharmapuri Vidysagar, MD; Leonard E. Weisman, MD; Stephen Welty, MD; T.F. Yeh, MD

### FREE Subscription - Qualified Professionals

Neonatology Today is available free to qualified medical professionals worldwide in neonatology and perinatology. International editions available in electronic PDF file only; North American edition available in print. Send an email to: [SUBS@Neonate.biz](mailto:SUBS@Neonate.biz). Include your name, title(s), organization, address, phone, fax and email.

### Sponsorships and Recruitment Advertising

For information on sponsorships or recruitment advertising call Tony Carlson at 301.279.2005 or send an email to [TCarlsonmd@gmail.com](mailto:TCarlsonmd@gmail.com)

### Meetings, Conferences and Symposiums

List your meeting on the Neonatology Today website; send an email to: [MEETING@Neonate.biz](mailto:MEETING@Neonate.biz). Include the meeting name, dates, location, URL and contact name.

### Corporate Offices

824 Elmcroft Blvd.  
Rockville, MD 20850 USA  
Tel: +1.301.279.2005; Fax: +1.240.465.0692

### Editorial and Subscription Offices

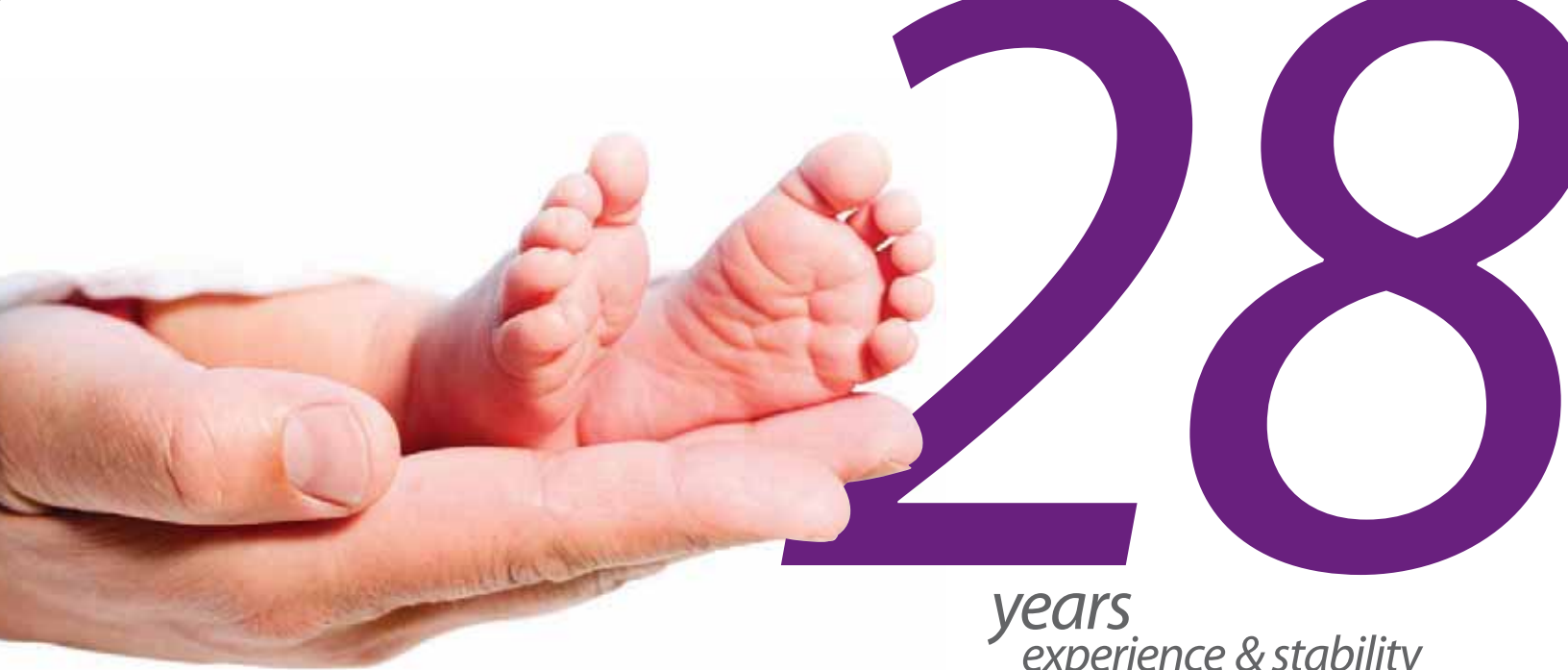16 Cove Road, Ste. 200  
Westerly, RI 02891 USA  
[www.NeonatologyToday.net](http://www.NeonatologyToday.net)

# MIAMI NEONATOLOGY 2010

34<sup>TH</sup> ANNUAL INTERNATIONAL CONFERENCE  
THE DIVISION OF NEONATOLOGY-DEPARTMENT OF PEDIATRICS

& ONE DAY WORKSHOP: ADVANCES IN NEONATAL RESPIRATORY CARE  
November 3-6, 2010; Fontainebleau, Miami Beach, FL

<http://neonatology.med.miami.edu/conference/>



28  
years  
experience & stability



**SHERIDAN**<sup>®</sup>  
CHILDREN'S SERVICES

*A Practice Management Group*

# Here We Grow!

The warmth of a close collegial group practice  
with the strength of a national organization.

### Pediatric Subspecialties:

- Neonatology
- Neonatal Nurse Practitioners
- Hospitalists
- Critical Care
- Emergency Medicine

VISIT US

**HOT  
TOPICS**  
IN NEONATOLOGY



Washington, DC  
December 05 - 08, 2010

**800.816.6791**

**childrens\_services@shcr.com**

**www.sheridanhealthcare.com**

"Sheridan" includes Sheridan Healthcare, Inc., its subsidiaries, affiliates and managed entities.

***Do you or your colleagues have interesting research results, observations, human interest stories, reports of meetings, etc. that you would like to share with the neonatology community?***

***Submit your  
proposed article to  
[RichardK@Neonate.biz](mailto:RichardK@Neonate.biz)***

*The final manuscript may be between  
400-4,000 words, and  
contain pictures, graphs,  
charts and tables.*